



HAL
open science

Digit replantation: From biomechanics to practical surgical applications.

Bruno Barbato, Anne-Virginie Salsac

► **To cite this version:**

Bruno Barbato, Anne-Virginie Salsac. Digit replantation: From biomechanics to practical surgical applications.. Hand Surgery and Rehabilitation, In press. hal-02504154

HAL Id: hal-02504154

<https://utc.hal.science/hal-02504154v1>

Submitted on 3 Jan 2021

HAL is a multi-disciplinary open access archive for the deposit and dissemination of scientific research documents, whether they are published or not. The documents may come from teaching and research institutions in France or abroad, or from public or private research centers.

L'archive ouverte pluridisciplinaire **HAL**, est destinée au dépôt et à la diffusion de documents scientifiques de niveau recherche, publiés ou non, émanant des établissements d'enseignement et de recherche français ou étrangers, des laboratoires publics ou privés.

Hand Surgery and Rehabilitation

Digit replantation: From biomechanics to practical surgical applications

--Manuscript Draft--

Manuscript Number:	HANSUR-D-19-00162R1
Article Type:	Literature Review
Keywords:	Replantation; Amputation; Fluid Biomechanics; Vein Graft; Anticoagulation
Corresponding Author:	BRUNO BARBATO aubergenville, FRANCE
First Author:	BRUNO BARBATO
Order of Authors:	BRUNO BARBATO Anne-Virginie Salsac
Abstract:	Digital amputations, which are always dramatic accidents with major functional and psychological repercussions, remain a surgical challenge. This article, dedicated to digital replantation, develop the underlying biomechanical and operative aspects as well as practical indications. The different stages from trauma to postoperative monitoring are described. We propose therapeutic procedures from theory to practice in order to optimize the operative gesture that must be the most effective in terms of time management and decision-making efficiency. Indications recognized as standards such as thumb amputation, multi-digital amputations and distal amputations are detailed, as well as the more controversial relocations such as for ring fingers. We see that the challenge of digital replantation success lies in the search for the best functional and cosmetic results and not in non-pertinent microsurgical exploit.

Digit replantation: From biomechanics to practical surgical applications

Replantations digitales : de la biomécanique à la pratique chirurgicale

Abstract

Digital amputations, which are always dramatic accidents with major functional and psychological repercussions, remain a surgical challenge. This article, dedicated to digital replantation, develop the underlying biomechanical and operative aspects as well as practical indications. The different stages from trauma to postoperative monitoring are described. We propose therapeutic procedures from theory to practice in order to optimize the operative gesture that must be the most effective in terms of time management and decision-making efficiency. Indications recognized as standards such as thumb amputation, multi-digital amputations and distal amputations are detailed, as well as the more controversial relocations such as for ring fingers. We see that the challenge of digital replantation success lies in the search for the best functional and cosmetic results and not in non-pertinent microsurgical exploit.

Résumé

Les amputations digitales, qui sont des accidents toujours dramatiques et aux répercussions fonctionnelles et psychologiques majeures, restent un challenge chirurgical. Dans cet article dédié aux replantations digitales, sont développés les aspects biomécaniques et opératoires sous-jacents, ainsi que des conduites pratiques. Nous décrivons les différentes étapes du traumatisme à la surveillance post-opératoire. Nous proposons des conduites à tenir partant de la théorie à la pratique dans le but d'optimiser le geste opératoire qui se doit d'être le plus efficace en termes de gestion du temps et d'efficacité décisionnelle. Les indications reconnues comme des standards telles que l'amputation du pouce, les amputations pluridigitales et les amputations distales sont détaillées, ainsi que les réimplantations plus controversées comme les doigts de bagues. Nous voyons que le challenge pour réussir une replantation digitale doit

être celui de la recherche du meilleur résultat fonctionnel et cosmétique et non de l'exploit
microchirurgical non pertinent.

Keywords: Replantation; Amputation; Fluid Biomechanics; Vein Graft; Anticoagulation

Mots-clés : Replantation ; Amputation ; Biomécanique des fluides ; Greffe veineuse ;
Anticoagulation

1
2
3
4
5
6
7
8
9
10
11
12
13
14
15
16
17
18
19
20
21
22
23
24
25
26
27
28
29
30
31
32
33
34
35
36
37
38
39
40
41
42
43
44
45
46
47
48
49
50
51
52
53
54
55
56
57
58
59
60
61
62
63
64
65

1. Introduction

1 The first recorded upper limb replantations were performed by Malt and McKhann [1] and by
2 Chen et al. [2], the former with an upper limb replantation and the latter with a hand
3 replantation, with doubt over who between them was the first [3]. Shortly after, the first
4 successful digital replantation was made by Komatsu and Tamai [4] and since then
5
6 improvements in microsurgical techniques have led to extend replantation indications.
7
8
9

10 The 1970s saw the rise of hand trauma centers, which combined training and practice of
11 three specialties within a single unit: microsurgery, reconstructive surgery and orthopedics [5].
12
13 This led to the concept of a one-time treatment [6].
14
15

16 As digit amputations largely affect the functional outcome of the hand, it is important to
17 promote effective and reproducible techniques, and guarantee that qualified surgeons reach a
18
19 high level of expertise in this demanding procedure.
20
21
22

23 In France, it has been shown that university degree programs in microsurgery are
24 heterogeneous [7]. The latest FESUM (Federation Européenne des services Urgences Mains)
25 publication showed that despite a 32% increase in the number of hand injuries over the last 20
26 years, the number of replantations represents only 7% of the microsurgical procedures and has
27 decreased [8]. The same trend has been observed in the USA, where the incidence of
28 replantation surgery has decreased by over 50% between 2000 and 2010, with most hand
29 surgeons performing fewer than five per year [9].
30
31
32
33
34
35
36
37
38

39 The surgical challenge represented by replantation is vascular success and regaining full
40 function. Although often rewarding for the surgeon, success must not be equated with tissue
41 survival, the end-goal of a reimplantation being its usefulness from a functional point of view.
42
43 This explains why indications have refocused and a new consensus for the reimplantation of the
44 thumbs, distal and multi-digit amputations have been reached, with broader indications for
45
46 instance in children. Detailed information on the management of digital amputations may be
47 found in the didactic and pedagogical articles [10-12].
48
49
50
51
52
53
54

55 In this article, the general principles of digital replantation are described. The consensual
56 indications are detailed as described above. We offer microsurgical tips and discuss
57
58 controversial indications, such as avulsion amputations, deducing from theory the key elements
59
60
61
62
63
64
65

for practice to optimize operative time and achieve the best possible cosmetic results and functional efficiency in replantation.

2. Fluid biomechanics considerations

To achieve a useful and functional status for a replanted finger, the first requirement is the restoration of blood circulation and successful vascular survival. "Plumbing" is thus the starting point for digital restoration. In order to understand the vascular and fluid mechanics causes of replantation failure, let us consider some classical biomechanics rules on flow patterns.

Poiseuille's experiments led to a better understanding of body flows, whenever they are quasi-steady and taking place in channels that are little tortuous and bifurcated (e.g. small blood vessels, air flow) [13]. They provided a strong argument for the no slip-condition of fluid on the wall of a pipe which determines the so-called friction factor. This strong dependence of the flow rate on the channel size allows the body to finely tune blood repartition through vasodilation and vasoconstriction. The corresponding laminar velocity profile is parabolic (Fig. 1A), the velocity being zero at the channel wall (no slip boundary condition) and maximum at the center of the channel.

Although Poiseuille law does not strictly apply to the large arteries, in which blood flow is strongly pulsatile, it still provides an estimate of the vessel hydraulic resistance. Such an estimate is essential to deduce values of the local blood flow Q in a given vessel, since in vivo blood flows are pressure-driven (and not flow-rate driven). It flows from high to low pressures.

Poiseuille also described the existence of a layer of plasma devoid of red blood cells along the vessel wall, which he observed in small blood vessels. The cell-free marginal layer is the consequence of the finite size of the red blood cells and of the lift force that they experience due to their deformability. This force makes the cells be subject to migration towards the center of the channel. This effect is now referred to as Zweifach-Fung effect [14,15].

In large arteries, Poiseuille equation does not apply, blood flow being pulsatile. The flow profiles in arteries were first derived by J. Womersley [16], who showed that they changed over time depending on the Womersley number:

$$\alpha = R \sqrt{\frac{\rho\omega}{\eta}}$$

with ω the blood flow pulsation ($\omega = 2\pi f$, with f the frequency). The Womersley number is a dimensionless number that compares the pulsatile inertial forces to the viscous forces in the blood flow. Since blood progresses along the vasculature from a large vessel to many small vessels, the tube radii consistently decrease, while the frequency, density and dynamic viscosity remain (usually) constant throughout the network. The Womersley number is, therefore, large in the aorta ($\alpha = 16$ to 18), decreases along with the vessel diameter at each vessel branching and reaches very small values in the terminal capillaries ($\ll 1$). The time evolution of the velocity profile has been shown within the abdominal aorta [17].

When the Womersley number is below 2.5, the frequency of the pulsations is sufficiently low, that a parabolic velocity profile has time to develop at each instant of the cardiac cycle. The quasi-steady flow is nearly in phase with the pressure gradient and can be well approximated by Poiseuille's law using the instantaneous pressure gradient.

In the arterioles, capillaries and venules, the Womersley numbers are much less than one. In these regions the inertial forces become negligible and the flow is determined by the balance between viscous and pressure forces. Stokes flow conditions thus dominate within the microcirculation.

Under physiological conditions, no transition to turbulence normally occurs within blood vessel. Turbulent flow conditions can, however, be found in certain conditions, such as stenosis, sharp turn of the flow, protrusions within the lumen (e.g. microvascular anastomosis stitches) (Fig. 1B). In the case of a long cylindrical pipe of constant cross section, the transition from laminar to turbulent flow is governed by the Reynolds number

$$N_R = \frac{\rho(2R)V}{\eta},$$

where $2R$ is the vessel diameter and V is a characteristic velocity, typically the mean velocity $V = Q/\pi R^2$. The transition is influenced by pulsatility [18]. No influence is observed in the high frequency limit ($\alpha \gtrsim 12$), as flow variations are too fast to impact turbulence (critical Reynolds number $N_{Rc} \sim 1800$). The same conclusion holds in the low Womersley regime ($\alpha \lesssim 2.5$), where

1
2
3
4
5
6
7
8
9
10
11
12
13
14
15
16
17
18
19
20
21
22
23
24
25
26
27
28
29
30
31
32
33
34
35
36
37
38
39
40
41
42
43
44
45
46
47
48
49
50
51
52
53
54
55
56
57
58
59
60
61
62
63
64
65

the flow structures adjust to the instantaneous Reynolds number ($N_{Rc} \sim 3000$). In the intermediate range of Womersley number ($2.5 \lesssim \alpha \lesssim 12$), the critical Reynolds number transits smoothly between the two N_{Rc} limits.

3. Efficient workflows and procedures in the replantation environment

3.1. Prior to patient arrival to the emergency department

Prior to patient arrival in the emergency department (ED), certain rules must be known and respected to optimize the rate of success:

- Transport of the amputated parts in ice packs without direct contact;
- No colored antiseptic solution as it can damage and color tissues;
- Special transportation boxes for amputated parts with time of injury and patient details;
- Exact time of the injury noted on the emergency report in order to get the ischemia time of the amputated part;
- No requirement of application of a tourniquet: compressive dressing is sufficient.

The classic teaching rule is six-hour ischemia time replantation as ischemia time influences rates of success and functional results, mostly in proximal replantation above hands.

In digital and distal amputations, longer ischemia times are not found to be detrimental to the success of digital replantation. Recent literature shows no significant statistical difference in survival rates below or above 12h of ischemia. Nonetheless, this is not to demonstrate that extended ischemia is well tolerated in finger replantation, but rather to suggest that delaying the replantation overnight can be considered [19-21].

3.2. Patient arrival to the emergency department

Upon arrival of the patient in the ED, the operating room (OR) staff and anesthesia teams should be notified. It is essential to eliminate any potentially life-threatening lesions or conditions which can delay replantation. X-rays of the patient hand and of the amputated part(s) are obtained as well as biological preoperative blood tests. A tetanus vaccination is given if indicated.

1
2
3
4
5
6
7
8
9
10
11
12
13
14
15
16
17
18
19
20
21
22
23
24
25
26
27
28
29
30
31
32
33
34
35
36
37
38
39
40
41
42
43
44
45
46
47
48
49
50
51
52
53
54
55
56
57
58
59
60
61
62
63
64
65

As soon as possible, the amputated part is delivered to the OR or both the patient and amputated part are sent together, but this must only occur after administrative registration in order to avoid patient error.

3.3. First steps in the operating room

The OR staff should prepare a side table with ice packs, a second set of microsurgical instruments, heparinized saline, micro and small vascular clip appliers, hand surgical instruments and 9-0 and 10-0 nylon sutures. Both the mini C-arm and operative microscope should be prepared, the former to confirm the type of bone osteosynthesis in the amputated part and the latter for side table dissection. The surgeon then takes the amputated part to the OR to prepare it for the replantation before the patient enters the theatre.

3.4. Amputated part status and advising the patient

This step determines the surgical strategy and order the priorities. This depend on the number of amputated fingers, the involvement of the thumb or not, and the macro and microscopic state of the fragments. A discussion with the patient should inform him of possible options and to secure their approval, considering age, medical history and profession. This explanatory time is very important, as the therapeutic process can be long with high functional consequences. A calm and confident relationship must be initiated by the surgeon. Following this discussion, the anesthetist performs the upper extremity block for the benefit of sympathetic blockade and subsequent vasodilatation. The non-surgical factors must be considered in the replantation decision especially psychiatric disorders which have been found correlated with poor outcomes and survival rates [21].

The amputated part is irrigated and washed carefully with saline solution without colored antiseptic. Direct observation of the amputated part under magnification and radiography of bone damage are essential to determine the type of the injury and distinguish between guillotine, crush or avulsion trauma. The most favorable case is the guillotine type, as it goes along with less vessel and tissue damage and thus entails less debridement. Crushing rarely occurs with trepan machines and tools. Crushing damage can be tiered and affect the bone

vessels and nerves at different degrees requiring more extensive debridement. The avulsion type, that often occurs in ring fingers, includes extensive damage to all the tendons, bones, vessels and nerves and requires a very particular and aggressive debridement as explained further on.

Clinical examination of the skin can reveal a “red line sign” or a “blue ribbon sign” with pulp ecchymosis indicating severe shearing force along the neuro-vascular bundle with extensive vessel injury, which requires important vessel debridement and may temper the replantation indication [22].

The amputated part is prepared under a magnifying loupe for skin debridement and assessing bone status. Mediolateral incisions are made, and the skins flaps are secured using 5-0 nylon sutures. A magnifying loupe is used to view more proximal amputated parts or a microscope for smaller parts, such as for the preparation of the distal phalanx arteries. Veins and nerves are tagged using 9-0 nylon leaving a thread of 1 cm in length, for easy secondary location.

Locating the dorsal veins requires caution in dorsal debridement to avoid damage and if too difficult, it should be considered at the tourniquet release time, when blood flow is restored. Digit irrigation with heparin solution is not systematic as reported in the literature [23,24]. Most authors stress that the insertion of a catheter into the lumen of the vessels of the severed part damages the intima. Tamai et al. also showed that in the case of crush amputations the amount of remaining blood was approximately twice as much as clear amputations, with microthrombi and tissue emboli seen mainly in veins of crush amputations. He proposed to irrigate crushed and avulsed digits prior to replantation [23]. According to FESUM investigations, only 40 % of French hand surgeons perform digit irrigation [24]. We recommend digit irrigation using a 24-gauge yellow catheter without cutting its extremity, as it causes a sharpening of the plastic catheter and damages the intima.

Bone resection, especially in the case of crush injuries is then made in order to avoid damage to the vessels and adjacent structures. Optimal skeletal shortening is important to ensure that vessels and soft tissue structures are nearly tension free, essentially in the diaphysis area. Bone shortening can also be made, if preparation for arthrodesis is required.

This is most frequent in distal replantation. Most often K-wires are used and inserted in the amputated part with the mini C-arm.

The distal part of a Tsuge suture or Kessler 4 strand core suture is placed in the flexor digitorum profundus, which is to be privileged. Reparation of the flexor digitorum superficialis (FDS) is often foregone in digital replantation in the interest of expediency, especially since it does not improve final function.

4. Operative time

4.1. Debridement

Both preparation of the amputated part and the debridement of the hand lead to predict and anticipate consecutive steps of the replantation.

The appropriate use of tourniquet time is paramount to efficient replantation. Firstly, debridement of the hand is made under tourniquet and must be as fast as the surgeon's experience allows. This first run tourniquet is mostly required for vessel examination and the extent of their debridement, in case of crush or avulsion mechanism and potential need for vein grafts. In the case of "red line sign" it often underlies a "tortuous arterial segment" that requires resection due to intimal disruption. If any doubt exists, then inflow check is required by deflating the tourniquet to ensure adequate flow. In this case the next two steps of the replantation osteosynthesis and extensor tendon repair can be achieved without the use of the tourniquet, especially in the setting of a multidigit replantation.

4.2. Bone and tendons repair

Bone preparation to attach the amputated skeletal uses the K-wires initially inserted into the amputated part, using "back and forth" motion, leaving free the PIP joint. In the medio diaphyseal area, the use of the bilboquet device is helpful for stability and timesaving especially in transmetacarpal and multiple digit amputations. This procedure can also be achieved using plate and screw constructs; however, in order to save time, the former technique is preferred (Fig. 2). Following bone stabilization, the extensor tendons are repaired with PDS® suture and at the same time the dorsal veins are easier to locate due to the absence of the tourniquet. Most

commonly the tourniquet is inflated at this time to continue with flexor tendon repair, using Tsuge or Kessler suture with microsurgical instruments to manipulate the tendon parts to reduce damage.

4.3 Microsurgical time

This usually occupies a large portion of the operating time in digit replantation. Set-up of the surgeon and operating field is crucial for timesaving.

4.3.1. Arterial repair

Direct arterial anastomosis of the digit dominant artery (ulnar artery for the thumb, index and middle, and radial for the ring and little) is recommended even with a cross arterial direct anastomosis (Fig. 3). Sometimes a vein graft is required due to the extent of arterial damage and length of resection on the aspect of intimal damage. A vein graft taken at the distal volar forearm needs to be returned and irrigated before intercalated suture. Attention must be paid to the adequate radius of the vein graft to avoid asymmetrical size mismatch although principles of vascular surgery can be applied as an oblique cut of the arterial stump when there are different outer diameters. This technique increases the risk for flow turbulences as shown by Biemer [25,26]. The use of a vein graft increases the rate of revascularization success compared to primary suturing in case of arterial loss [27-30] (Fig. 4). The vein graft length must be considered as in physiological tension to avoid overlength graft that causes “kinking” phenomenon, origin of turbulent flow and thrombosis (Fig. 5). More rarely, venae comitantes of the radial artery at the wrist should be considered especially as their diameter is constant but rarely used in practice.

Although various microvascular anastomosis techniques include suture-less anastomosis as Laser-Assisted Micro-Anastomosis (LAMA) [31] or fibrin-glue anastomosis [32], in fact, arterial anastomosis is generally performed using interrupted 10-0 nylon sutures at the digit area or 11-0 for distal amputations with the use of Tamai’s disposable double plastic micro clips or Ikuta retractor. For distal anastomosis, free clamp sutures can be performed for the central pulp artery as so called” first back wall repair” [33].

1
2
3
4
5
6
7
8
9
10
11
12
13
14
15
16
17
18
19
20
21
22
23
24
25
26
27
28
29
30
31
32
33
34
35
36
37
38
39
40
41
42
43
44
45
46
47
48
49
50
51
52
53
54
55
56
57
58
59
60
61
62
63
64
65

In our experience in order to decrease the risk of transfixion sutures, we use a looping suture type on the last two to three sutures. The needle and suture are passed two or three times without suture section, in order to leave the anastomosis lumen open (Fig. 6).

When multiple digit replantation is performed the tourniquet may be deflated and reflatd to assist with the remnant arterial anastomosis.

4.3.2. *Nerve repair*

Nerve repair is a critical component of the procedure, the success of which may affect long-term functionality of the digit. In the decade 2000-2010, as many publications on techniques of peripheral nerves repair were published as there were in the entire preceding half century 1950-2000 [34]. A direct nerve suture is always recommended. When a tension-free neurorrhaphy is not possible, nerve grafts are often required. Options include vein conduits for substance loss of less than 2-3 cm or absorbable nerve guides mainly in proximal amputations at the hand or transmetacarpal. We do not consider these options necessary in addition to direct nerve suture, as they cause delays. In our experience, the new generation of neurotubes essentially synthetic cause major inflammatory reaction and discomfort in digit area [35]. Autograft options include medial antebrachial cutaneous nerve, posterior interosseous nerve or nerves harvested from spare parts in the case of multiple digits amputation known as “spare-parts finger” concept [36].

4.3.3. *Venous repair*

When possible, venous anastomoses are performed while the tourniquet remains inflated. In distal replantation the tourniquet can be released to provide the added benefit of vein distension and location, and re-inflated to perform the venous anastomoses. Two veins for one artery are required to ensure optimal venous drainage and decrease the risk of thrombosis [37] (Fig. 3).

Venous graft is required if no direct anastomosis is possible.

4.3.4. *Skin closure*

The tourniquet is deflated to check vessels anastomosis using patency test and the condition of eventual vein graft, especially as they distend and distend significantly. Papaverine and tepid

1 serum can be used for vasodilatation digit. Coloration is ensured. Bipolar coagulation precedes
2 skin closure which is performed without any tension. Skin full thickness grafts can be used for
3 resurfacing directly on veins or grafts veins on the dorsal aspect of the digit.
4
5

6 *4.3.5. Dressing*

7
8 The dressing is an important step of the procedure and is the responsibility of the surgeon. The
9 task should not be delegated. The fat gauzes are applied in a linear and non-circular way as are
10 compresses. A splint is made to keep the hand and replanted digits secure avoiding any
11 untimely motion and leaving the pulp free for examination. The first dressing is made by the
12 surgeon.
13
14
15
16
17
18
19
20
21

22 *4.3.6. Postoperative care protocol*

23 Clinical examination for evaluation of temperature, digit pulp color and edema with capillary refill
24 performed hourly in the first 12 hours and thereafter, every two hours for the next 72 hours, as
25 per hand surgeon protocol. Examinations are performed by trained nursing staff and reported
26 on the patient's record. The use of warming agents such as heating lamps is discouraged as
27 there is no evidence of improved rate of success in microsurgical procedures [38].
28
29
30
31
32
33
34

35 Tobacco smoking should be prohibited to guarantee optimal circulation [39,40]. However
36 a recent meta-analysis did not find a significant effect of smoking on the digit survival rate [21].
37
38

39 A personalized relationship of trust is needed between the patient and the surgeon who
40 is the preferred interlocutor of the follow-up.
41
42
43
44
45

46 **5. Complications and immediate postoperative pharmacologic and environmental** 47 **support**

48 **5.1. Complications**

49
50 The most common complications are arterial and venous thrombosis. Venous thrombosis is the
51 first cause of replantation failure. Arterial thromboses are found to be three times as common as
52 venous but has a more favorable outcome. The salvage rate of digital replantation complicated
53 by arterial thrombosis is noted to be 30%, whereas it is only 7% for venous occlusion [41-42].
54
55
56
57
58
59
60
61
62
63
64
65

1
2
3
4
5
6
7
8
9
10
11
12
13
14
15
16
17
18
19
20
21
22
23
24
25
26
27
28
29
30
31
32
33
34
35
36
37
38
39
40
41
42
43
44
45
46
47
48
49
50
51
52
53
54
55
56
57
58
59
60
61
62
63
64
65

The risk for thromboses is highest (80%) during the first two postoperative days and decreases to 10% after postoperative day three. This risk pattern is attributed to the initially low flow volume through the pedicle.

Experienced clinical staff can evaluate the arterial or venous origin of the suffering digit. The early onset of venous congestion can be elicited by the “throbbing sign” described by Leung, even before any obvious color changes.” *It is elicited by pinching the digit between the thumb and finger of the examiner until the skin blanches. Releasing the pressure slowly, a sensation of throbbing will be felt synchronous with the patient’s pulse rate*” [43].

The first step is the removal of the dressing, splint, and finally the skin sutures to release any extrinsic compression. If the status worsens or does not resolve, the patient may be returned to the OR for exploration and likely revision of anastomosis is performed to save the digit. This is typically accomplished with resection of the thrombosed area with subsequent primary anastomosis or vein graft. The use of intravascular pharmacologic thrombolysis with agents such as streptokinase or urokinase can be an option to increase the salvage success rate [44]. However, it is not routinely recommended due to limited evidence and publications.

5.2. Pharmacological support

Arterial thrombosis platelet aggregation is the underlying cause of arterial thrombosis whereas venous thrombosis is primarily the result of fibrin clotting, theoretically making aspirin the preferred agent for arterial thrombosis and heparin the better anticoagulant for venous thrombosis [45].

The appropriate timing of anticoagulation therapy maximizes its effectiveness. The first two days after surgery are crucial in anticoagulation because most of the clots form during this time. Aspirin is widely used [24,46]. The bleeding risk is dose-dependent and a low dose regimen (75mg/kg) minimizes this risk [46]. As such, the standard dose is 160 mg per day for adults and is to be continued depending on individual surgeon’s advice, between 15 to 30 days. Low-molecular-weight heparin (LMWH) is administered during the recovery phase in prophylactic dosage. The vasodilate effect of heparin may reduce thrombosis further by increasing the rate of blood flow [47]. The data from Khoury et al. suggests that the only method

of anticoagulation that is statistically significantly associated with decreased odds of thrombosis is subcutaneous heparin [48].

Dextran has been used because its antithrombotic effect is mediated by a reduction of erythrocyte aggregation and platelet adhesiveness. The increased risk of complications, such as anaphylaxis or acute renal failure or cerebral edema with dextran, makes it unattractive candidate for routine thromboprophylaxis.

Although anticoagulation treatment is a part of replantation surgery, anticoagulation protocols vary widely among microsurgeons. Therefore, current recommendations for microsurgical anticoagulation therapy are based on an extrapolation of conflicting animal data and scant human studies [49]. The importance of salvaging a replanted digit must be weighed against the risk of a blood transfusion. The single agent regimen, in addition to aspirin (heparin or dextran), was associated with an average drop in hematocrit of 6% and an incidence of blood transfusion of 2%. Multiple-agent (3) therapy produced an average drop in hematocrit of 15% and an incidence of blood transfusion of 53% [50]. We do not recommend the combination of three agents. We recommend Aspirin for 15 days associated with LMWH in prophylactic dosage during recovery phase with a platelet survey.

Medicinal leeches relieve venous congestion both actively, as a result of the bloodletting action, and passively, by direct injection into the host of hirudin from within the leech saliva that is more potent than heparin [47,51]. Previous experience with leech therapy has been mostly after very distal replantation and was reported with a high salvage rate [52,53]. More recent publications indicate that use of leeches for four and half days seems to lead to a higher rate of digital survival but increasing the rate of blood transfusions as well, up to 57% [54,55]. We do not recommend the use of leeches beyond three days and essentially for distal replantations.

6. The essentials

6.1. The thumb

The thumb is the guest star of replantation and it is probably for that reason that the first digital replantation using microvascular techniques was of a completely amputated thumb, as achieved by Komatsu and Tamai in 1968 [4].

1
2
3
4
5
6
7
8
9
10
11
12
13
14
15
16
17
18
19
20
21
22
23
24
25
26
27
28
29
30
31
32
33
34
35
36
37
38
39
40
41
42
43
44
45
46
47
48
49
50
51
52
53
54
55
56
57
58
59
60
61
62
63
64
65

Since this time, there is a strong consensus supporting the replantation of thumbs regardless of age, mechanism and condition of the amputated part, as the overall function of the replanted thumb is mostly good when compared to the high level of global handicap of a hand with a missing thumb [56-59]. The commonly used classification of thumb amputation is the Merle classification [60].

The particularity of the human thumb position, out of the plane of the fingers, makes the performance of arterial reconstruction difficult. The injured hand must be held in maximum supination with wrist flexion facilitated by the Tupper hand retractor; however it remains uncomfortable for the duration of microsurgery replantation. Because of the frequent difficulty to expose the proximal arterial stumps, even more so after debridement, this leads to frequent use of a vein graft in thumb replantation. The preplacement of venous interposition graft to the digital artery stumps in the amputated thumb prior to the osteosynthesis improves the patency rate and the ischemia time [61] (Fig. 7).

After amputated reattachment the proximal anastomosis is performed at the radial artery with a short exposition at the anatomical snuffbox under the EPL, which is a good location of the radial artery (Fig. 8). In multiple digit amputations the notion of the spare parts bank is mostly pertinent in the case of amputated thumb (missing) or when the thumb is not replantable due to extensive damage. In this case the least damaged digit is replanted in transpositional digital microsurgery.

6.2. Distal replantation

With the advancement of microsurgical techniques single digit amputation distal to the FDS insertion and fingertip amputations are now considered a good indication for replantation due to optimal aesthetic and functional outcomes [52,62,63] (Fig. 8).

Several classifications have been described for distal digital replantation [64]. The Ishikawa classification is widely used, as it predetermines the possibility of repairing both an artery and a vein and the possibility or not of a venous outflow anastomosis [65] (Fig. 9). Indeed, the success rates of amputations distal to the DIP joint have been reported between 70 and 90 % when an artery and a vein are repaired [64].

1
2
3
4
5
6
7
8
9
10
11
12
13
14
15
16
17
18
19
20
21
22
23
24
25
26
27
28
29
30
31
32
33
34
35
36
37
38
39
40
41
42
43
44
45
46
47
48
49
50
51
52
53
54
55
56
57
58
59
60
61
62
63
64
65

The operative procedures are carried out simultaneously on the amputated part and on the finger (Fig. 10). The osteosynthesis is simpler in distal amputation as an axial K-wire or needle is enough to assure skeletal stability. Two oblique skin incisions are made on the palmar surface, and triangular flaps are elevated, as described by Tsai et al, in order to facilitate the exposure [66]. the distal arterioles deriving from the distal arch of the digital arteries (size:0.85+/- 0.1mm) are selected. The so-called pulp central artery is commonly used for anastomosis, even more so with the detour of this arcade to permit length gain in case of artery defect and favor end-to-end anastomosis, in order to avoid a venous graft in this minute environment [67].

Ultra-microsurgical techniques involve a vascular anastomosis of less than 0.5 mm with four to six stiches using 11-0 nylon with a 50-µm needle. At this level the use of micro clamps is useless, and a first back wall repair is usually performed.

In zones 3 and 4, a dorsal terminal vein can usually be anastomosed. Its size is approximately 1mm at the level of DIP joint [68].

The flexibility to forego a venous anastomosis is sometimes impossible as the amputation is more distal to zone 3 and the DIP joint. However, replantation distal to the DIP joint often presents difficulties in finding a suitable drainage vein in the amputated part. If two arteries are available at this level, it has been suggested that to satisfy outflow from artery-only-replants:

- the use of an arteriovenous fistulae in place of venous drainage by anastomosing a second digital artery available to a palmar vein [65];
- the Zhang technique; it consists in anastomosing the two arteries, and ligating the larger one proximal to the DIP joint. The ligation of the artery proximal to the recurrent vessels stops blood flow from the body. Thus, the outflow continues through arteriovenous communication and recurrent vessels to the dorsal digital veins [69].

If no vein can be repaired the procedure is referred to as an artery-only replantation.

Finally, if nerve repair cannot be done as we reach the tuft level, then a neurotization effect will allow for a correct sensitive recovery [70].

1
2
3
4
5
6
7
8
9
10
11
12
13
14
15
16
17
18
19
20
21
22
23
24
25
26
27
28
29
30
31
32
33
34
35
36
37
38
39
40
41
42
43
44
45
46
47
48
49
50
51
52
53
54
55
56
57
58
59
60
61
62
63
64
65

The skin closure requires particular attention. We de-epidermize the stump skin of the amputated part and the proximal digit bank on 1-2mm each. Closure is then made, overlaying the two de-epidermized surfaces. This increases the cutaneous surface contact and the venous neo-connections (Fig. 10F).

In case of no venous drainage available a controlled bleeding is initiated as soon as surgery ends. We create an incision in the distal pulp to provide for venous egress and heparin scrubs are performed at the bed side every hour. Use of leeches can help in case of venous congestion. The controlled bleeding is associated with anticoagulation therapy protocol. Time required for intrinsic venous outflow is between four to six days.

6.3. Digit avulsion

Replantation of a complete ring finger avulsion has been debated and long considered a flawed treatment choice due to poor functional results [71-74].

They represent a serious reconstruction challenge for the hand surgeon. Existing classification systems specify which elements condition the functional prognosis and allow the indications for replantation to be expanded [71,75-78]. We use the Urbaniak [71] classification revised by Kay et al. [77] and subdivision of the class IV according to Adani et al. [75] (Table 1). The replantation technique has been reported particularly by Foucher et al. [27]. We would like to suggest the following tips (Fig. 11):

After debridement of the damaged tissues, the palmar proper digital artery is exposed using a short hemi Bruner incision at the DIP joint on the dominant vascular side, while avoiding any splitting of the sheath. It is important to spare and not damage the contralateral artery, otherwise transverse anastomotic arterial network will not allow reverse contralateral perfusion. This cutaneous transverse anastomotic pattern has already been studied by Michel Salmon [79].

The skeletal osteosynthesis time can be difficult as high caution is required on the digital sheath. Most of the time a DIP arthrodesis is performed using intramuscular needle cap as protection to avoid traumatic dissection of the distal phalanx. The K-wires are inserted “back and forth” through the needle cap to achieve DIP fixation [80].

1
2
3
4
5
6
7
8
9
10
11
12
13
14
15
16
17
18
19
20
21
22
23
24
25
26
27
28
29
30
31
32
33
34
35
36
37
38
39
40
41
42
43
44
45
46
47
48
49
50
51
52
53
54
55
56
57
58
59
60
61
62
63
64
65

The choice between direct anastomosis and the use of a vein graft for arterial repair is made after microscopic examination of the proximal stump artery and when a proximal arterial thrombosis exceeds 1 cm. The use of a vein graft increases the rate of revascularization success compared to primary suturing [28-30,80-84]. Following distal anastomosis of the vein graft, the subcutaneous passage of the venous and repositioning of the degloving part is facilitated by using liquid sterile Vaseline. The proximal anastomosis is performed close to the common palmar digital artery bifurcation where the microscopic conditions are better. Nerve repair is frequently difficult due to the stretching injury. In our practice, the proximal dominant stretched nerve is inserted distal in the sheath in a neurotization procedure. A nerve graft from an uninjured site is not recommended

The key to maximum functional recovery is the very early auto mobilization of the functional and uninjured PIP joint [80].

Digit primary resection has been recommended by a few authors [72-74]. We think it is judicious to discuss amputation in a second procedure, after a period of time, following the initial microsurgical management, in order to ensure patient consent.

Prevention of avulsion has been advocated and several devices to pre-weaken rings to make them less traumatic have been developed [85]. Prevention should not be limited to awareness but include introduction of and adherence to manufacturing standards [86].

According to the different classifications and authors the indication of replantation of complete ring fingers are essentially those distal at the FDS insertion and mostly the DIP joints. Without obfuscating the moral harm that can be caused by the loss of a finger in a young adult the replantation in case of proximal avulsion especially with PIP dislocation does not lead to a reasonable functional outcome beyond the vascular success. The motivation of both the surgeon and patient must be considered. The functional and esthetic outcomes are also dependent upon postoperative care and management (Fig. 12).

6.4. Skin defect management

When soft tissue defects lead to vessels or bone exposure especially on the dorsal aspect of the replanted finger, then use of cutaneous venous flaps have been promoted for tissue

1 coverage, as well as venous repair for outflow restoration. For the thumb we recommend the
2 use of the kite flap described by Foucher [87] (Fig. 13) and Vilain's flag flap [88] for the other
3 digits in ring finger avulsion (Fig. 11E). Both flaps require only one end anastomosis for the
4 venous drainage. In case of dorsal defect, the use of a dorsal flag flap from the adjacent digit
5 should be considered, in order to bring soft tissue and vein graft.
6
7

8 Free cutaneous venous flaps were first used using the dorsal skin of the foot [89]. Later,
9 the dorsal aspect of an uninjured digit was used, increasing the survival rate of the flap when
10 compared to the forearm donor site [90]. The venous free flap is more commonly used to
11 reconstruct segmental defects in the digital artery and for palmar simultaneous soft tissue
12 coverage [91]. However, their disadvantages are twofold: they can be a time-consuming part of
13 the operation as they require an entirely new microsurgical procedure and they have no
14 superiority to pedicle flaps as previously described at least at the proximal part of the digit.
15
16
17
18
19
20
21
22
23
24
25

26 6.5. Transmetacarpal replantation

27 This challenging injury is different from more proximal or distal injuries in that the lumbrical and
28 interosseous muscles lie within the zone of injury. A high incidence of digital survival following
29 transmetacarpal replantation has been shown. However, ischemia of the intrinsic muscles plays
30 a key role in the poor functional results. The earliest description of blood supply to the intrinsic
31 muscles by Salmon [92] and more recently [93] show that the lumbricals receive blood supply
32 from both the deep and superficial palmar arches.
33
34
35
36
37
38
39
40
41

42 To achieve maximum blood flow restoration one should perform multiple vein grafts on
43 all available distal arteries. This can be made by direct VY vein graft (Fig. 14) or by using the
44 dorsal venous arches of the foot [94]. The potency of one common digital vessel alone provided
45 blood flow to all fingers through transverse and commissural vessels connecting the digital
46 vessels proximal to the interphalangeal joints (Fig. 15). Retrograde flow to the adjacent common
47 digital vessels revascularizes the other digits [95,96].
48
49
50
51
52
53
54

55 Despite successful revascularization of the digits, the intrinsic muscles are left ischemic
56 in the "middle ground" in the palm of the hand with resultant sclerosis and contracture.
57
58
59
60
61
62
63
64
65

Resection of the involved intrinsic musculature and adequate metacarpal shortening (at least 12 mm) should be considered [97].

6.6. Multi-digit amputations

Such dramatic injuries require high-level and immediate decision making in order to maximize the best functional outcome with important and essential procedural steps to be followed:

- Team concept for strategic decision and multi surgeons for simultaneous surgery [98,99]. Depending on the surgeon's preference and situation the synchronous or sequential technique can be used, the latter being most commonly practiced today [100].
- Creative use of "spare parts bank" to improve priority digit replantation [36,101].
- Digital transposition permits placing of the most usable part in the most effective position.
- Replantation priorities: the highest priority is salvaging the thumb, which invites every type of creative technique, from the amputated thumb part to the use of spare parts and finally digital transposition.

At this point of the decision-making process, it is important to understand that each patient is an individual case. The number of digits useful for replantation drives the process along with finding the equilibrium for the most useful function of the hand from reconstruction of the radial aspect of the hand (emphasizing the two or three-point pinch) to the ulnar side reconstruction emphasizing the power grasp. In any case, the index position is the one to be least considered.

7. Conclusion

Replantation procedure is a moral contract between the surgeon and his patient from the initial surgical decision making to postoperative care and management.

Whether single or multi digital amputation, it is essential to follow guidelines for efficacy in the determining, operative and postoperative stages. Table 2 provides a condensed

schematic and practical viewpoint of efficient and timesaving workflow to achieve the best functional and cosmetic results.

1
2
3
4 **Disclosure of interest**
5

6 The authors declare that they have no competing interest.
7
8
9

10 *Acknowledgements* : The authors thank Marc Donon for his illustrative drawings and
11 professionalism.
12
13
14
15
16
17
18
19
20
21
22
23
24
25
26
27
28
29
30
31
32
33
34
35
36
37
38
39
40
41
42
43
44
45
46
47
48
49
50
51
52
53
54
55
56
57
58
59
60
61
62
63
64
65

References

- [1] Malt RA, McKhann C. Replantation of severed arms. JAMA 1964;189:716-22.
- [2] Chen CW, Chien YC, Pao YS. Salvage of the forearm following complete amputation: report of a case. Chin Med J 1963;82:633-8.
- [3] Fan KW. Ronald Malt or Chen Zhongwei: Who performed the first surgical replantation? J Med Biogr 2018 Jan 1:967772018773968. <https://doi.org/10.1177/0967772018773968>.
- [4] Komatsu S, Tamai S. Successful replantation of a completely cut-off thumb. Plast Reconstr Surg 1968;42:374-7.
- [5] Vilain R. L'aventure de SOS Mains. In: Jeux de Mains. Paris: Artaud, 1987: 333-40.
- [6] Michon J, Merle M, Foucher G. Traumatismes complexes de la main, traitement tout en un temps avec mobilisation précoce. Chirurgie 1977;103:956-64.
- [7] Alzakri A, Al-Rajeh M, Liverneaux PA, Facca S. État des lieux de l'enseignement des techniques microchirurgicales en France et à l'étranger. Chir Main 2014;33:219-23.
- [8] Raimbeau G. In: Livre blanc: Etat des lieux des urgences de la main en France, Montoux: Sodinprim; 2018, p. 19-26.
- [9] Payatakes AH, Zagoreos NP, Fedorcik GG, Ruch DS, Levin LS. Current practice of microsurgery by members of the American Society for Surgery of the Hand. J Hand Surg Am 2007;32:541-7.
- [10] Dautel G, Vincelet Y. Replantations digitales. In: EMC-Techniques chirurgicales-Orthopédie-Traumatologie 2016 ;11(2) :1-16 [Article 44-380].
- [11] Barbary S, Dap F, Dautel G. Finger replantation: Surgical technique and indications. Chir Main 2013;32:363-72.
- [12] Safa B, Greyson MA, Eberlin KR. Efficiency in replantation/revascularization surgery. Hand Clin 2019;35:131-41.
- [13] Poiseuille JLM. Recherches expérimentales sur les mouvements de liquides dans les tubes de très petits diamètres. C R Acad Sci 1840;11:1041-8.
- [14] Svanes K, Zweifach BW. Variations in small blood vessel hematocrits produced in hypothermic rats by micro-occlusion. Microvasc Res 1968;1:210-20.
- [15] Fung YC. Stochastic flow in capillary blood vessels 1973;5:34-48.

[16] Womersley JR. Method for the calculation of velocity, rate of flow and viscous drag in arteries when the pressure gradient is known. *J Physiol* 1955;127:553-63.

[17] Salsac AV, Sparks SR, Chomaz JM, Lasheras JC. Evolution of the wall shear stresses during the progressive enlargement of symmetric abdominal aortic aneurysms. *J Fluid Mech* 2006;560:19-51.

[18] Long Q, Xu XY, Ramnarine KV, Hoskins P. Numerical investigation of physiologically realistic pulsatile flow through arterial stenosis. *J Biomech* 2001;34:1229-42.

[19] Woo SH, Cheon HJ, Kim YW, Kang DH, Nam HJ. Delayed and suspended replantation for complete amputation of digits and hands. *J Hand Surg Am* 2015;40:883-9.

[20] Cavadas PC, Rubi C, Thione A, Pérez-Espadero A. Immediate versus overnight-delayed digital replantation: comparative retrospective cohort of survival outcomes. *J Hand Surg Am* 2018;43:625-30.

[21] Ma Z, Guo F, Qi J, Xiang W, Zhang J. Effects of non-surgical factors on digital replantation survival rate: a meta-analysis. *J Hand Surg Eur* 2016;41:157-63.

[22] van Beek AL, Kutz JE, Zook AG. Importance of the ribbon sign, indicating unsuitability of the vessel, in replanting a finger. *Plastic Reconstr Surg* 1978;61:32-5.

[23] Tamai S, Tatsumi Y, Shimizu T, Hori Y, Okuda H, Takita T, Sakamoto H, Fukui A. traumatic amputation of digits: the fate of remaining blood. *J Hand Surg Am* 1977;2:13-21.

[24] Dumont LA, Rongièrès M, Tchénio P, Gangloff D, Garrido-Stowhas I. Etude multicentrique sur la prévention de la thrombose en microchirurgie du membre supérieur. Enquête auprès de la FESUM. *Chir Main* 2010;29:100-8.

[25] Biemer E. Vein grafts in microvascular surgery. *Br J Plast Surg* 1977;30:197-9.

[26] Biemer E. Definitions and classifications in replantation surgery. *Br J Plast Surg* 1980;33:164-8.

[27] Foucher G, Citron N, Merle M, Dury M. Revascularization of digital avulsion injuries caused by rings. *Ann Chir Main* 1986;5:256-9.

[28] Hyza P, Vesely J, Drazan L, Stupka I, Ranno R, Castagnetti F. Primary vein grafting in treatment of ring avulsion injury. *Ann Plast Surg* 2007;59:163-7.

- [29] Akyurek M, Safak T, Reçik A. Ring avulsion replantation by extended debridement of the avulsed digital artery and interposition with long venous graft. *Ann Plast Surg* 2002;48:574-81.
- [30] Dautel G, Voche P. Replantations digitales. In: *Chirurgie de la main. L'urgence* 4^{ème} ed. Paris, Elsevier Masson 2016 : 427-71.
- [31] Leclère FM, Schoofs M, Vogt P, Casoli V, Mordon S. 1950-nm diode laser-assisted microanastomoses (LAMA): an innovative surgical tool for hand surgery emergencies. *Laser Med Sci* 2015;30:1269-73.
- [32] Cho AB, Wei TH, Torres LR, Junior RM, Rugiero GM, Aita MA. Fibrin glue application in microvascular anastomosis: comparative study of two free flaps series. *Microsurgery* 2009;29:24-8.
- [33] Harris GD, Finseth F, Buncke HJ. Posterior-wall-first microvascular anastomotic technique. *Br J Plast Surg* 1981;34:47-9.
- [34] Abbou R, Beck M, Zemirline A, Facca S, Liverneaux P. Techniques de réparation des nerfs périphériques: évolution de la littérature de 1950 à 2010. *Chir Main* 2011;30:363-7.
- [35] Braga Silva J, Marchese GM, Cauduro CG, Debiasi M. Nerve conduits for treating peripheral nerve injuries: A systematic literature review. *Hand Surg Rehabil* 2017;36:71-85.
- [36] Foucher G. Le doigt banque. In: Foucher G (ed) *Le traitement primaire des traumatismes de la main*. Paris : Expansion scientifique française; 1992 : 146-52.
- [37] Mefano JI, Rizis D, Landes G, Bou-Merhi J, Harris PG, Danino MA. Impact of the number of veins repair in short-term digital replantation survival rate. *J Plastic Reconstr Aesthet Surg* 2016;69:640-5.
- [38] Matheron AS, Lequin T, Facca S, Liverneaux P. Faut-il encore utiliser la lampe chauffante en microchirurgie? *Chir Main* 2011;30:323-6.
- [39] Van Adrichem LNA, Hovius SER, van Strik R, van der Meulen JC. The acute effect of cigarette smoking on the microcirculation of a replanted digit. *J Hand Sur Am* 1992;17:230-4
- [40] Wei DH, Strauch RJ. S. Smoking and hand surgery. *J Hand Surg Am* 2013;38:173-9.
- [41] Morrison WA, McCombe D. Digital replantation. *Hand Clinics* 2007;23:1-12.
- [42] Morrison WA, Mitchell GM, Hickey MJ. Late occlusion of microvascular vein grafts in replantation. *J Hand Surg Am* 1998;23:1106-11.

[43] Leung PC. The “throbbing sign” – an indication of early venous congestion in replantation surgery. *J Hand Surg Am* 1979;4:409-11.

[44] Loisel F, Pauchot J, Gasse N, Meresse T, Rochet S, Tropet Y, Obert L. Adjonction d'antithrombotiques in situ en cas de replantation digitale: étude prospective préliminaire de 13 cas. *Chir Main* 2010;29:326-31.

[45] Li X, Cooley BC. Effect of anticoagulation and inhibition of platelet aggregation on arterial versus venous microvascular thrombosis. *Ann Plast Surg* 1995;35:165-9.

[46] Fitzmaurice DA, N Blann AD, Lip GYH. Bleeding risks of antithrombic therapy. *BMJ* 2002;325:828-31.

[47] Askari M, Fisher C, Weniger FG, Bidic S, Lee WP. Anticoagulation therapy in microsurgery: A review. *J Hand Surg Am* 2006;31:836-46.

[48] Khoury RK, Sherman R, Buncke HJ, Feller AM, Hovius S, Benes CO. A phase II trial of intraluminal irrigation with recombinant human tissue factor pathway inhibitor to prevent thrombosis in free flap surgery. *Plast Reconstr Surg* 2001;107:408-15.

[49] Shi G, Meister D, Daley RA, Cooley BC. Thrombodynamics of microvascular repairs: effects of antithrombotic therapy on platelets and fibrin. *J Hand Surg Am* 2013;38:1784-9.

[50] Furnas HJ, Lineaweaver W, Buncke HJ. Blood loss associated with anticoagulation in patients with replanted digits. *J Hand Surg Am* 1992;17:226-9.

[51] Arami A, Gurevitz S, Palti R, Menachem S, Berelowitz M, Yaffe B. The use of medicinal leeches for the treatment of venous congestion in replanted or revascularized digits. *J Hand Surg Am* 2018;43;949.e1-e5.

[52] Foucher G, Norris RW. Distal and very distal digital replantation. *Br J Plast Surg* 1992;45:199-203.

[53] Whitaker IS, Oboumarzouk O, Rozen WM, Naderi N, Balasubramanian SP, et al. the efficacy of medicinal leeches in plastic and reconstructive surgery: a systematic review of 277 reported clinical cases. *Microsurgery* 2012 32:240-50.

[54] Lee ZH, Cohen JM, Daar D, Anzai L, Hacquebord J, Thanik V. Quantifying outcomes for leech therapy in digit revascularization and replantation. *J Hand Surg Eur* 2019;44:414-8.

[55] Buntic RF, Brooks D. Standardized protocol for artery-only fingertip replantation. J Hand Surg Am 2010;35:1491-6.

[56] Mitz V, Louthuy B, Staub B, Leviet D, Vilain R, et al. Réimplantation du pouce. Technique, indications, résultats. A propos de 50 cas. Acta Orthop Belg 1981;47:806-21.

[57] Tamai S. Twenty years' experience of limb replantation-review of 293 upper extremity replants. J Hand Surg Am 1982;7:549-56.

[58] Earle MJ, Watson JS. Twenty-four thumb replantations. J Hand Surg Br 1984;9:98-102.

[59] Soucacos PN. Indications and selection for digital amputation and replantations. J Hand Surg Br 2001;26:572-81.

[60] Merle M, Dap F, Foucher Guy, Bouchon Y, Michon J. Réimplantation et revascularisation du pouce Problèmes techniques et résultats. A propos de 125 cas. Chirurgie 1984;110:255-65.

[61] Shafiroff BB, Palmer AK. Simplified technique for replantation of the thumb. J Hand Surg Am 1981;6:623-4.

[62] Dautel G, Ferreira AP, Corcella D, Merle M. replantations digitales distales. La Main 1997;2:329-35.

[63] Matzuzaki H, Yoshizu T, Maki Y, Tsubokawa N. Functional and cosmetic results of fingertip replantation: anastomosing only the digital artery. Ann Plast Surg 2004;53:353-9.

[64] Hatori Y, Doi K, Sakamoto S, Yamasaki H, Wahegaonker A, Addosooki A. Fingertip replantation. J Hand Surg Am 2007;32:548-55.

[65] Suzuki Y, Ishikawa K, Isshiki N, Takami S. Fingertip replantation with an efferent A-V anastomosis for venous drainage: clinical reports. Br J Plast Surg 1993;46:187-91.

[66] Tsai TM, McCabe SJ, Maki Y. A technique for replantation of the fingertip. Microsurgery 1989;10:1-4.

[67] Strauch B, Moura W. Arterial system of the fingers. J Hand Surg Am 1990;15:148-54.

[68] Lucas GL. The pattern of venous drainage of the digits. J Hand Surg Am 1984;9:448-50.

[69] Zhang X, Wen S, Wang B, Wang Q, Li C, Zhu H. Reconstruction of circulation in the fingertip without vein repair in zone I replantation. J Hand Surg Am 2008;33:1597-1601.

[70] Faivre S, Lim A, Dautel G, Duteille F, Merle M. Adjacent and spontaneous neurotization after distal digital replantation in children. Plast Reconstr Surg 2003;111:159-65.

- [71] Urbaniak JR, Evans JP, Bright DS. Microvascular management of ring avulsion injuries. *J Hand Surg Am* 1981;6:25-30.
- [72] Segret J, Barbary S, Pétry D, Gautel G. Primary ray resection as an alternative to microsurgical replantation in the management of ring finger avulsion. *Chir Main* 2008;27:202-7.
- [73] O'Brien BM. Replantation and reconstructive microvascular surgery. Part I. *Ann Roy Coll Surg Engl* 1976;58:87-103.
- [74] Biemer E. Experience in replantation surgery in the upper extremity. *Ann Acad Med Singapore* 1979;8:393-7.
- [75] Adani R, Castagnetti C, Busa R, Caroli A. Ring avulsion injuries: microsurgical management. *J Reconstr Microsurg* 1996;12:189-94.
- [76] Barbary S. Plaies complexes: replantations. In: Liverneaux P, Chantelot C (éds) *La traumatologie des parties molles de la main*. Paris: Springer; 2011.:269-91.
- [77] Kay S, Werntz J, Wolff TW. Ring avulsion injuries: classification and prognosis, *J Hand Surg Am* 1989;14:204-13.
- [78] Nissenbaum M. Class IIA ring avulsion injuries: an absolute indication for microvascular repair. *J Hand Surg Am* 1984;9:810-5.
- [79] Salmon M. *Les artères de la peau: Etude anatomique et chirurgicale*. Paris, Masson 1936:44-7.
- [80] Hamouya A, Barbato B, Beauthier-Landauer V, Hémon C. Complete ring finger avulsion: Review of 16 years of cases at a Hand Emergency Unit. *Hand Surg Rehabil* 2018;37:206-11.
- [81] Adani R, Pataia E, Tarallo L, Mugnai R. Results of replantation of 33 ring avulsion amputations. *J Hand Surg Am* 2013;38:947-56.
- [82] Tsai TM, Manstein C, DuBou R, Wolff TW, Kutz JE, Kleinert HE. Primary microsurgical repair of ring avulsion amputation injuries. *J Hand Surg Am* 1984;9:68-72.
- [83] Ozkan O, Ozgentaş HE, Safak T, Dogan O. Unique superiority of microsurgical repair technique with its functional and aesthetic outcomes in ring avulsion injuries. *J Plast Reconstr Aesthet Surg* 2006;59:451-9.
- [84] Schoofs M, Leps P, Millot F, Migaud H. Revue de trente arrachements digitaux par mécanisme de bague. *Ann Chir Main* 1990;4:245-51.

[85] Dubert T, Diop A, Voeltzel P. An experimental study of ring avulsion injuries and two preventives devices. *J Hand Surg Br* 2000; 25:418-21.

[86] Matheron AS, Hendriks S, Gouzou S, Liverneux PA, Facca S. Can ring finger injuries be prevented by pre-fragilized rings? About three clinical cases. *Chir Main* 2014;33:204-6.

[87] Foucher G. Le Lambeau cerf-volant. *Ann Chir* 1978;32:593-6.

[88] Vilain R, Dupuy JF. Use of the flag flap for coverage of a small area on a finger or the palm. 20 years experience. *Plast Reconstr Surg* 1973;51:397-401.

[89] Honda T, Nomura S, Yamauchi S, Shimamura K, Yoshimura M. The possible applications of composite skin and subcutaneous vein graft in the replantation of amputated digits. *Br J Plast Surg* 1984;37:607-12.

[90] Tsai TM, Matiko JD, Breidenbach W, Kutz JE. Venous flaps in digital revascularization and replantation. *J Reconstr Microsurg* 1987;3:113-9.

[91] Lee DC, Kim JS, Roh SY, Lee KJ, Kim YW. Flap coverage of dysvascular digits including venous flow-through flap. *Hand Clin* 2019;35:185-97.

[92] Salmon M, Dor J. Les artères des muscles du membre et du tronc. Paris, Masson, 1933.

[93] Weinzweig N, Starker I, Sharzer LA, Fleegler EJ. Revisitation of the vascular anatomy of the lumbrical and interosseous muscles. *Plast Reconstr Surg* 1997;99:785-90.

[94] Merle M, Dautel G. Plaies complexes et mutilations des mains : replantations distales du membre supérieur. In: *EMC-Techniques chirurgicales-Orthopédie-Traumatologie* 1992 ;6p [Article 44-385].

[95] Nakamura J, Kinoshita Y, Hama H, Ishimori Y. Successful replantation of four fingers with a single common digital artery anastomosis. *J Microsurg* 1980;2:53-7.

[96] Tonkin MA, Ames EL, Wolff TW, Larsen RD. Transmetacarpal amputations et replantation: The importance of the normal vascular anatomy. *J Hand Surg Br* 1988;13:204-9.

[97] Meyer VE, Mailard G, Maass D, Azzoni Z. Successful replantation of a hand amputated through the metacarpus. *J Bone Joint Surg Br* 1976;58:474-7.

[98] Kim WK, Lee JM, Lim JH. Eight cases of nine-digit and ten-digit replantations. *Plastic Reconstr Surg* 1996; 98:477-84.

[99] Baek SM, Kim SS. Ten digit and nine-digit replantation (4 cases). Br J Plast Surg
1992;45:407-12.

[100] Urbaniak JR. Digit and hand replantation: current status. Neurosurgery 1979;4:551-9.

[101] Foucher G, Braun FM, Merle M, Michon J. Le doigt « banque » en traumatologie de la
main. Ann Chir 1980;34:693-8.

1
2
3
4
5
6
7
8
9
10
11
12
13
14
15
16
17
18
19
20
21
22
23
24
25
26
27
28
29
30
31
32
33
34
35
36
37
38
39
40
41
42
43
44
45
46
47
48
49
50
51
52
53
54
55
56
57
58
59
60
61
62
63
64
65

Table titles

Table 1. Classification of ring finger injuries: Urbaniak [71] revised by Kay et al. [77] and subdivision of the class IV injuries according to Adani et al. [75]

Table 2. Guide to efficiency and time saving in digit replantations

Figure legends

Fig. 1. Laminar flow in Poiseuille's law. Poiseuille's law describes the laminar flow of an incompressible fluid through a long tube of constant cross section. It provides the relationship between flow rate and pressure drop (A). Turbulent flow conditions (B). ρ : density; η : viscosity; Q : flow rate; Δp : pressure difference; L : length of the tube; R : channel radius; N_R : Reynolds number.

Fig. 2. Bone stabilization: K-wires (A); screws (B); plate (C); bilboquet (D).

Fig. 3. Vessels repair: Parts preparation (A). Direct arterial anastomoses (B). Cross arterial anastomosis (C). Dorsal venous anastomoses (D).

Fig. 4. Vein graft for arterial reconstruction: direct repair (A); cross repair (B).

Fig. 5. "Kinking" phenomenon in vein.

Fig. 6. Looping suture type.

Fig. 7. Preplacement venous graft in thumb replantation.

Fig. 8. Distal amputation: preoperative condition (A); postoperative view (B); final functional and cosmetic results (C,D).

Fig. 9. The Ishikawa classification for distal amputations and applications for vessels and nerve repair.

Fig. 10. Distal replantation: replantation preparation (A); oblique skin incisions for larger exposure (B); central artery pulp anastomosis (C) with the detour of this arcade to permit length gain and favor end to end anastomosis (D); palmar vein anastomosis (E); closure overlaying the two de-epidermized surfaces (F); dorsal vein anastomosis in zone 3 and 4 (G).

Fig. 11. Ring finger avulsion: preoperative status (A); distal artery exposure and preparation for bone fixation (B); prior distal vein graft anastomosis (C); replantation and proximal artery anastomosis (D); flag flap for skin coverage and venous flow restoration (E).

Fig. 12. Ring finger avulsion: preoperative view (A); final Results (B,C).

Fig. 13. Venous kite flap for dorsal loss skin of the thumb (donor site) (A). Dorsal venous flow restoration (B).

Fig. 14. Restoration of transmetacarpal arterial flow by direct VY venous graft.

Fig. 15. Restoration of blood flow using a single artery digit through digital transverse and commissural vessels.

1
2
3
4
5
6
7
8
9
10
11
12
13
14
15
16
17
18
19
20
21
22
23
24
25
26
27
28
29
30
31
32
33
34
35
36
37
38
39
40
41
42
43
44
45
46
47
48
49
50
51
52
53
54
55
56
57
58
59
60
61
62
63
64
65

Dear reviewers

Thank you for your interest in this article and your comments

Concerning reviewers 1

Changes have been made in the revised manuscript :article and not lecture

A shower is not always required as the stress of patient and organization is difficult at the time of injury and not seem to be notified in the manuscript

The figures are not free of rights because I made them and paid for with Marc Donon professional medical drawer me.donon is his signature

Concerning Reviewers 2

The 3 very interesting history biblio have been added ; life threatening lesions and explanatory time have been mentioned; Ikuta added; nerve conduits and biblio added with the commentary that this procedure should not delay time efficiency when a direct nerve suture is possible ;platelet survey mentioned; a figure 10F shows the de-epidermized technique with more explanation in the text

Reviewers 3 thanks

Thank so much for your comments and interest

Sincerely yours

Digit replantation: From biomechanics to practical surgical applications

Replantations digitales : de la biomécanique à la pratique chirurgicale

B. Barbato¹, A.-V. Salsac²

1: Urgences Main Val de Seine, Centre hospitalier privé du Montgardé, 32, rue de Montgardé, 78410 Aubergenville, France

2: Laboratoire de Biomécanique et Bioingénierie (UMR 7338), CNRS-Université de Technologie de Compiègne, Alliance Sorbonne Université, rue du Docteur Schweitzer, CS 60319, 60203 Compiègne cedex, France

Auteur correspondant:

Bruno Barbato

Urgences Main Val de Seine, Centre hospitalier privé du Montgardé, 32, rue de Montgardé, 78410 Aubergenville, France

Tel : 0611740228

E-mail : bdb.barbato@wanadoo.fr

Autre auteur :

Anne-Virginie Salsac

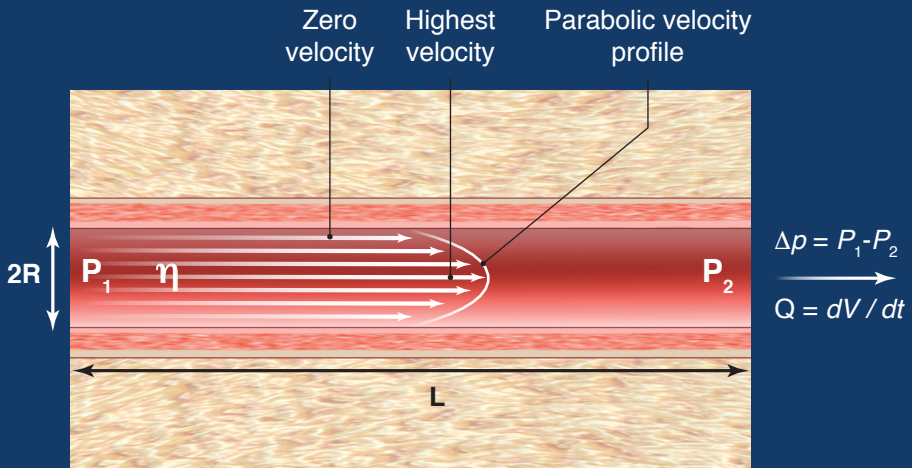
Laboratoire de Biomécanique et Bioingénierie (UMR 7338), CNRS-Université de Technologie de Compiègne, Alliance Sorbonne Université, rue du Docteur Schweitzer, CS 60319, 60203 Compiègne cedex, France

E-mail : anne-virginie.salsac@utc.fr

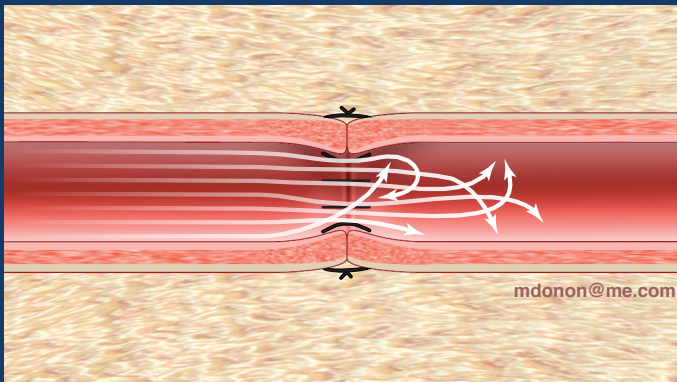
Conférence d'enseignement qui sera présentée au GEM Décembre 2019

A

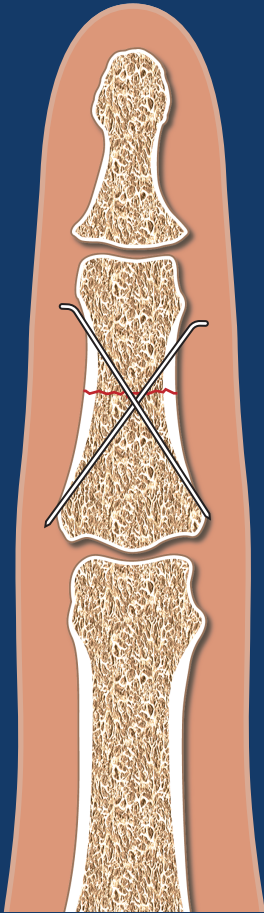
$$Q = \frac{dV}{dt} = \frac{\Delta p \pi R^4}{8 \eta L}$$



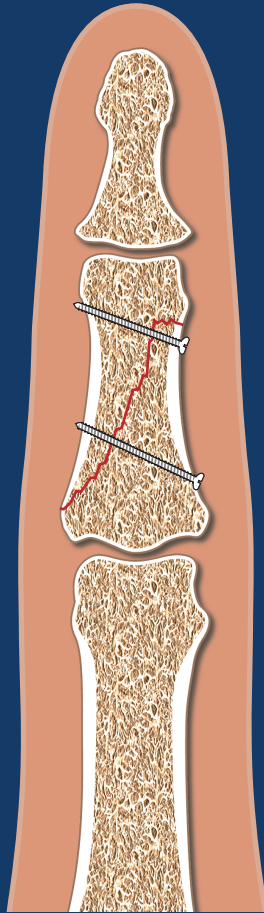
Laminar flow - $N_R < 2000$

B

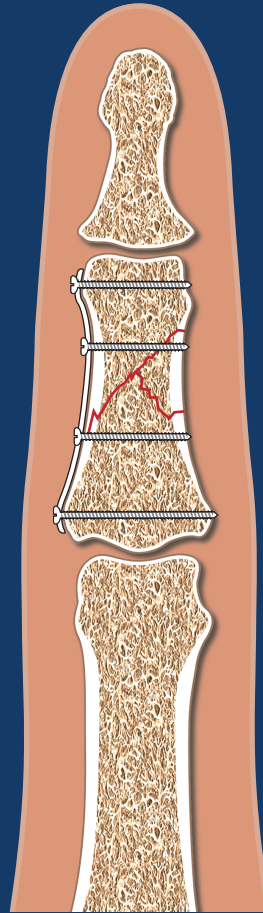
Turbulent flow - $N_R > 2000$



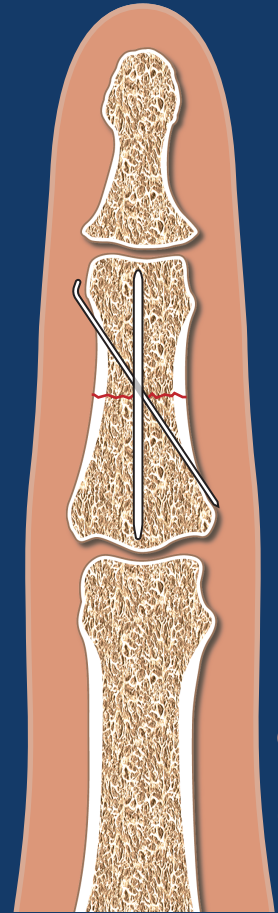
A



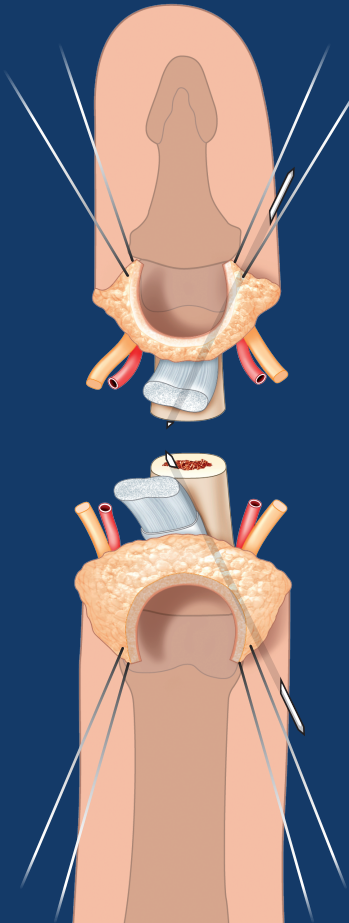
B



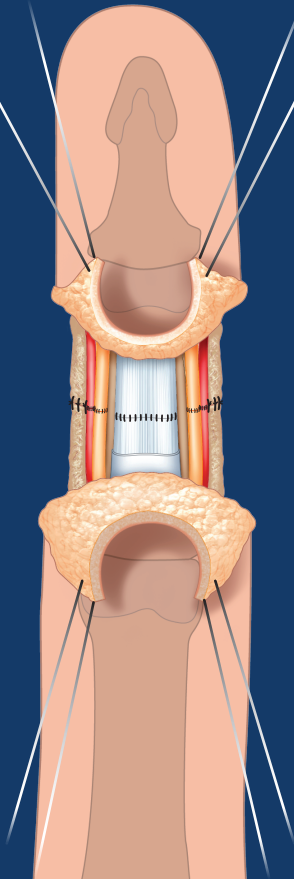
C



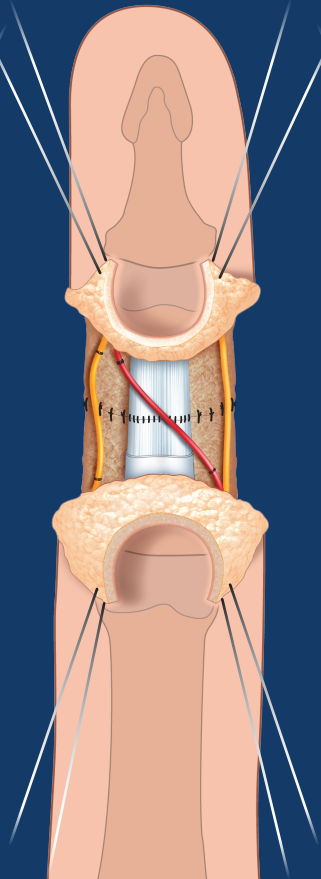
D



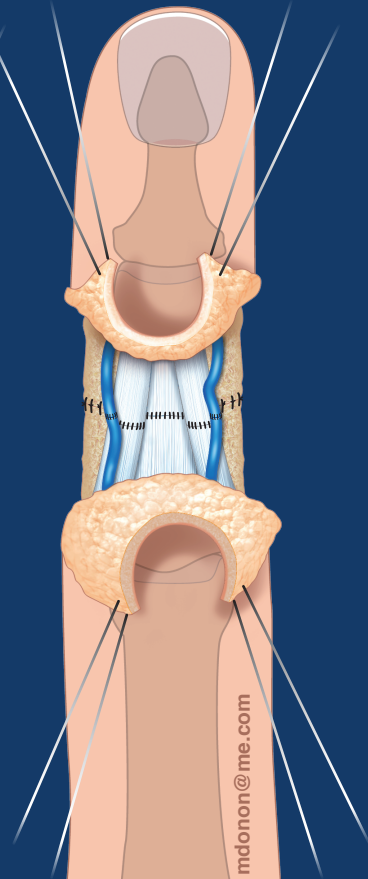
A



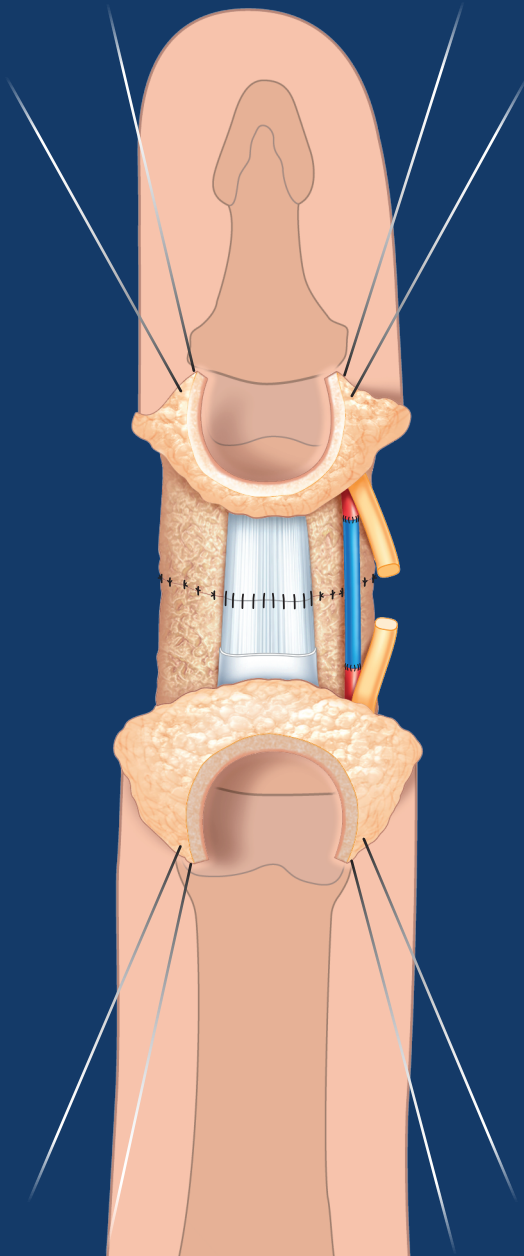
B



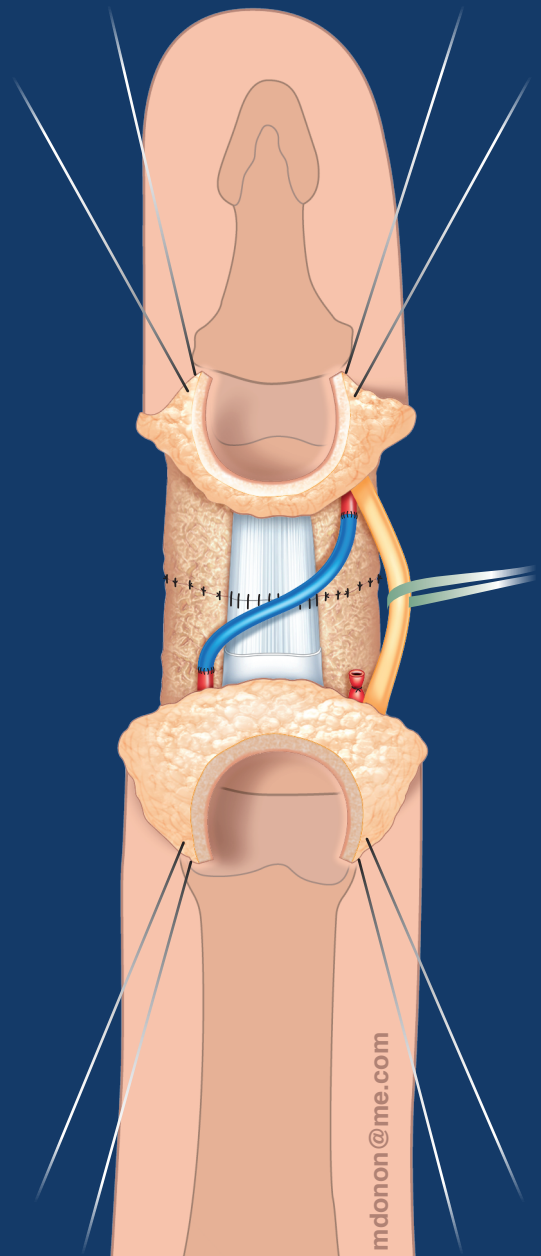
C




D

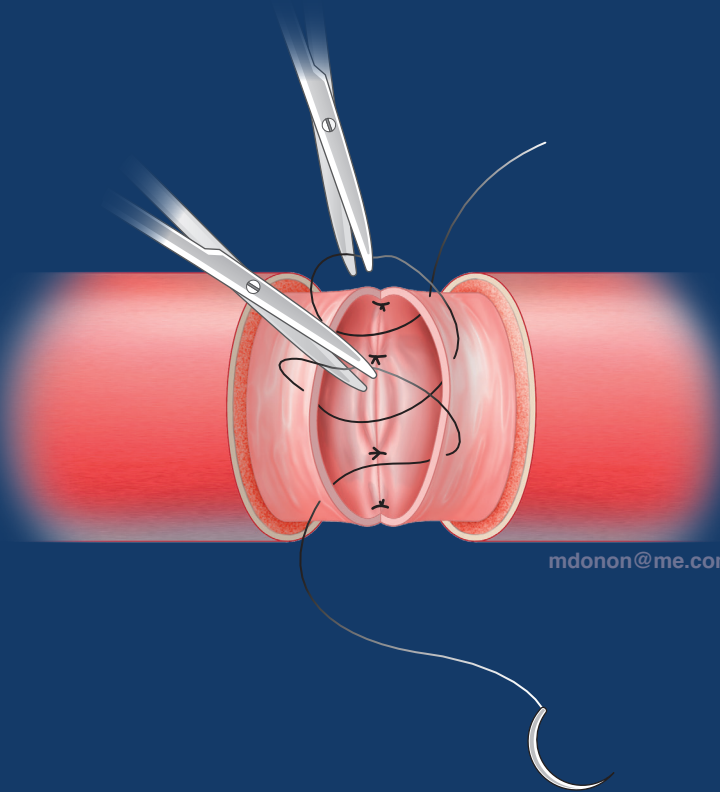


A



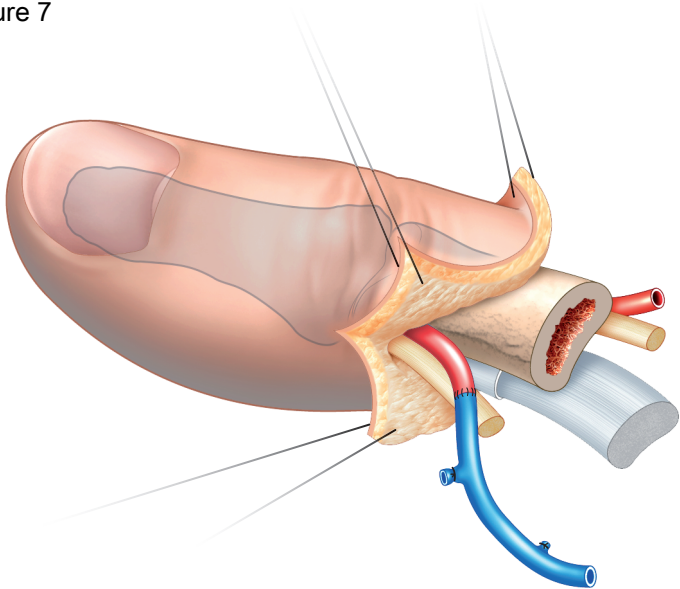
B

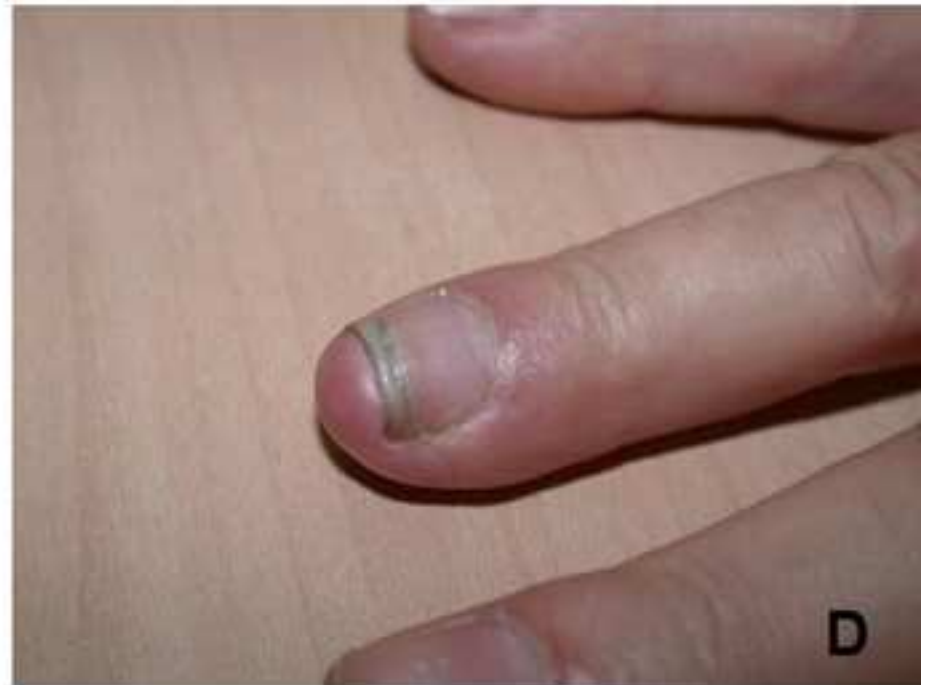
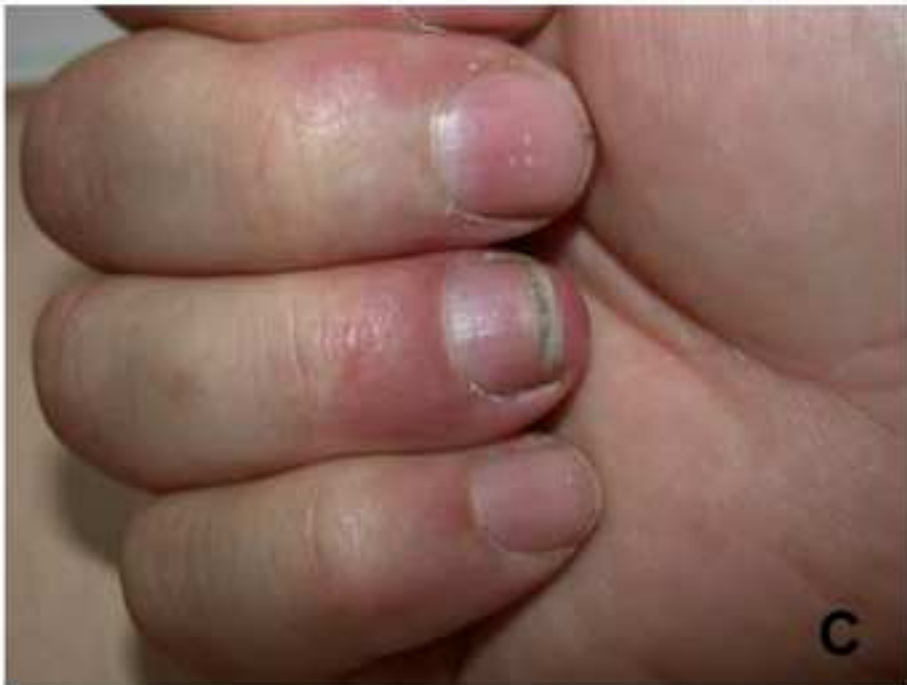
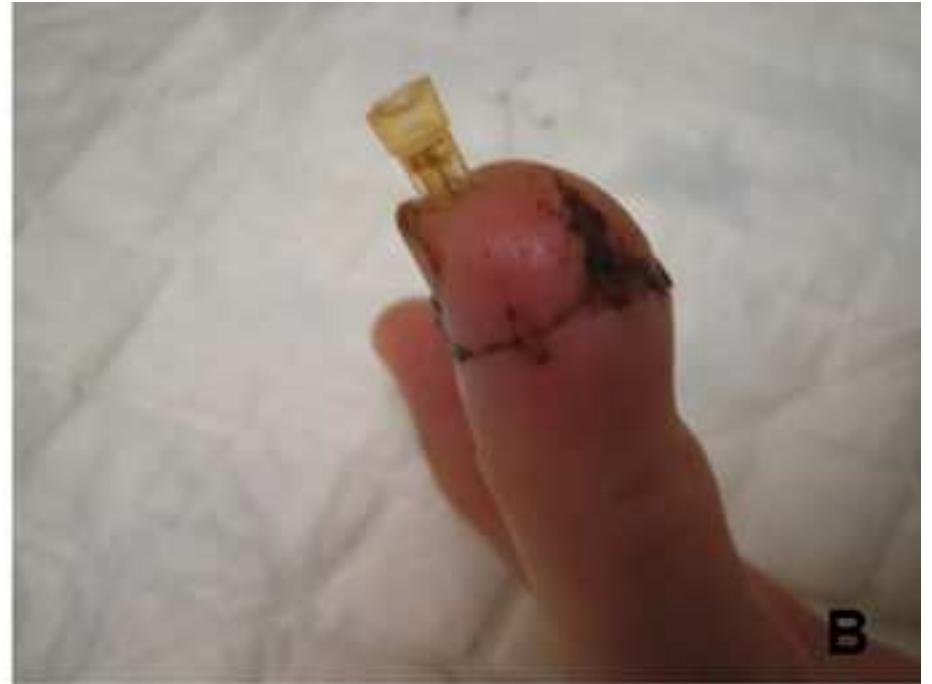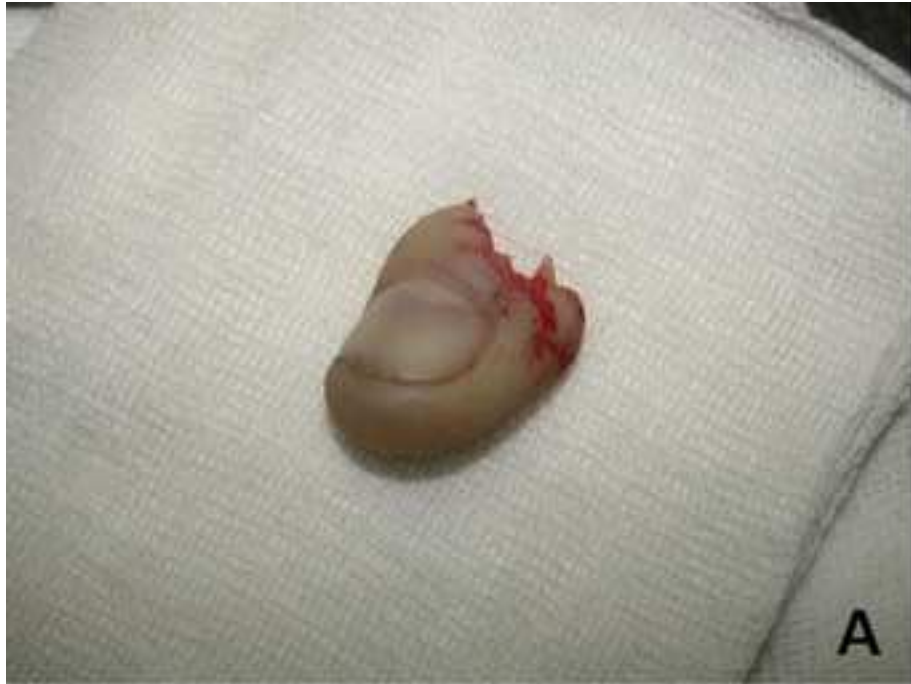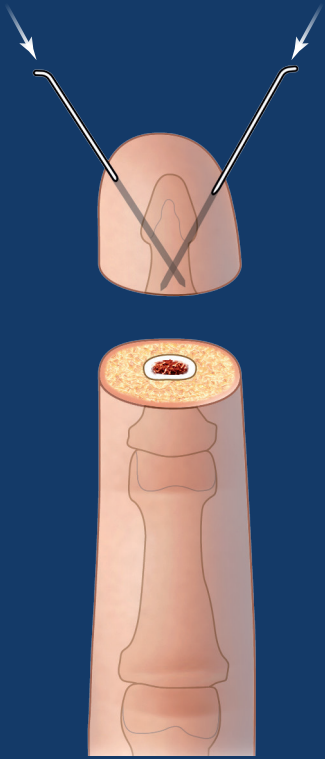


mndonon@me.com

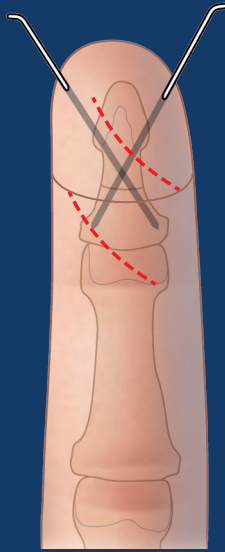
Figure 7



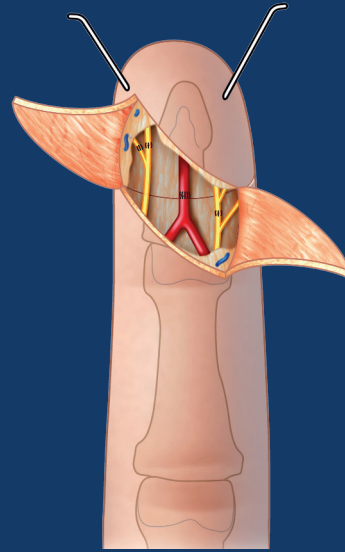




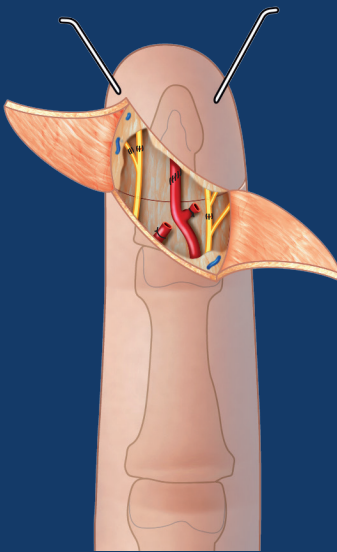
A



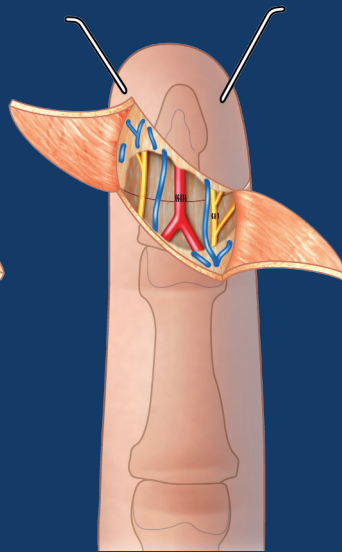
B



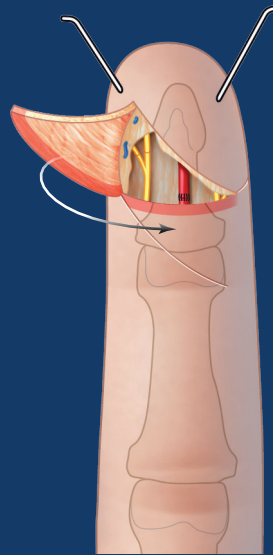
C



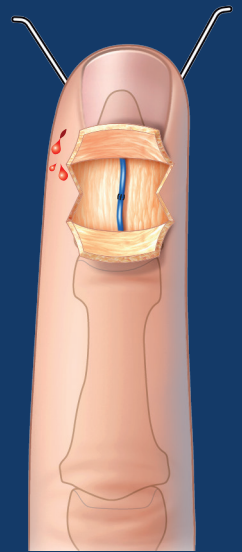
D



E



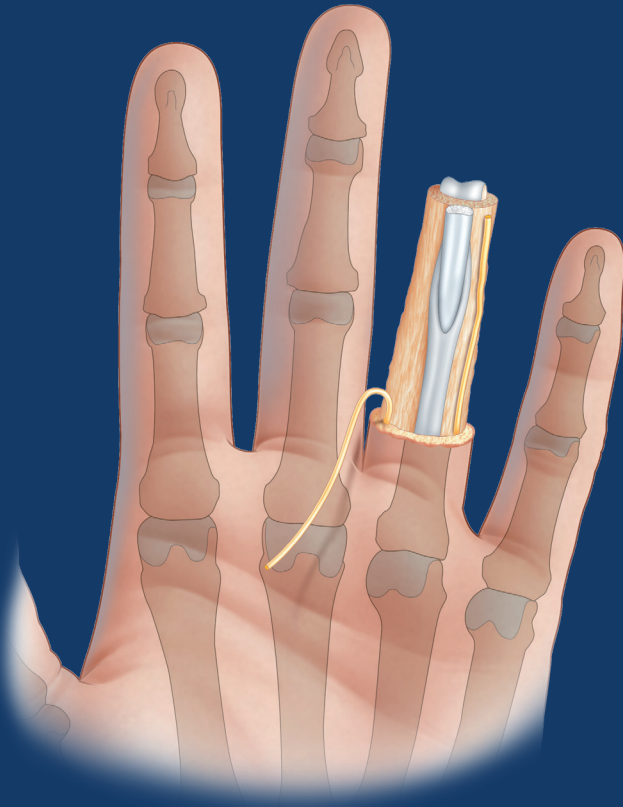
F



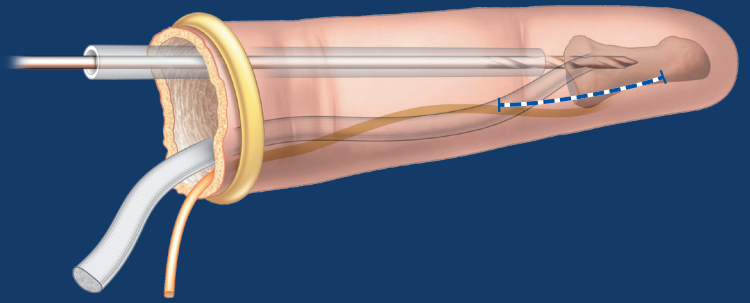
G

Figure 11

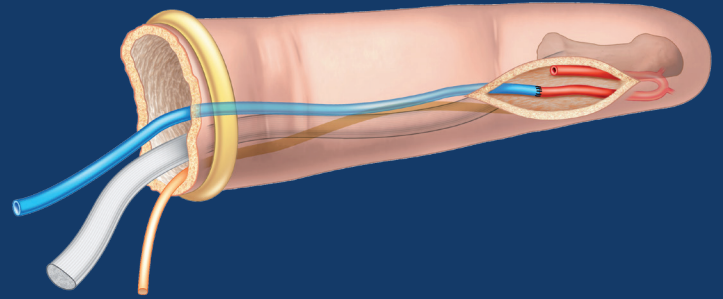
A



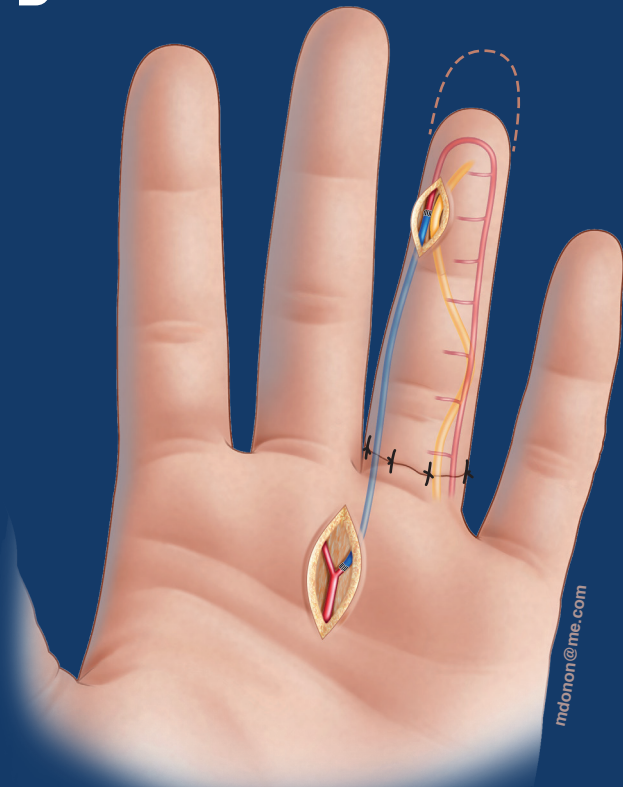
B



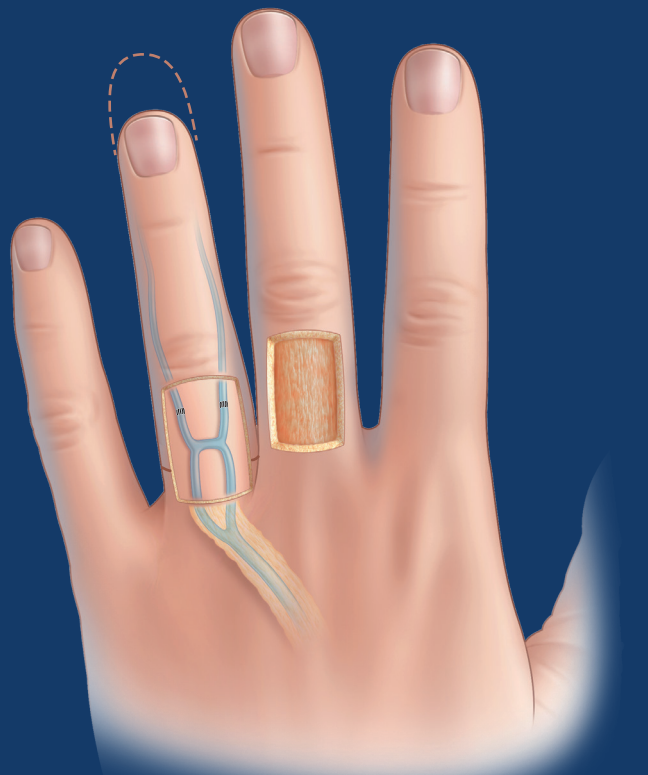C



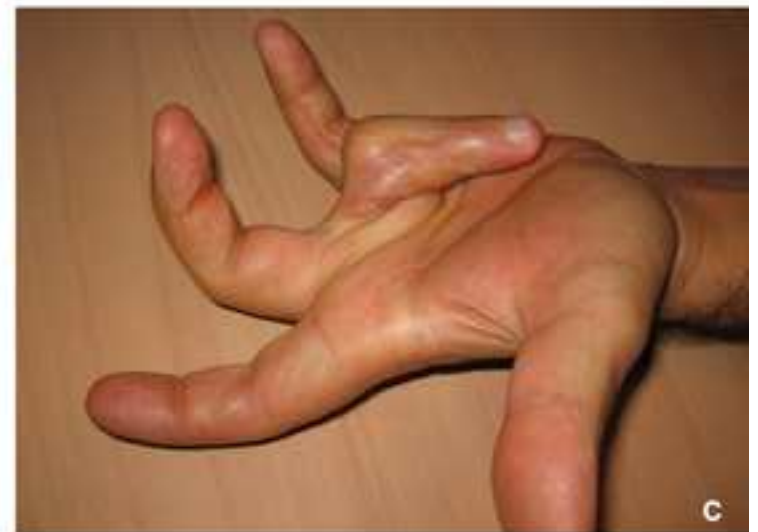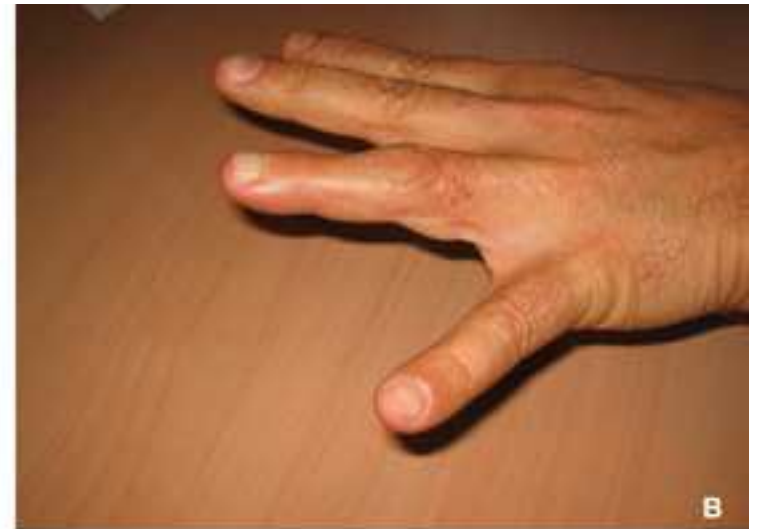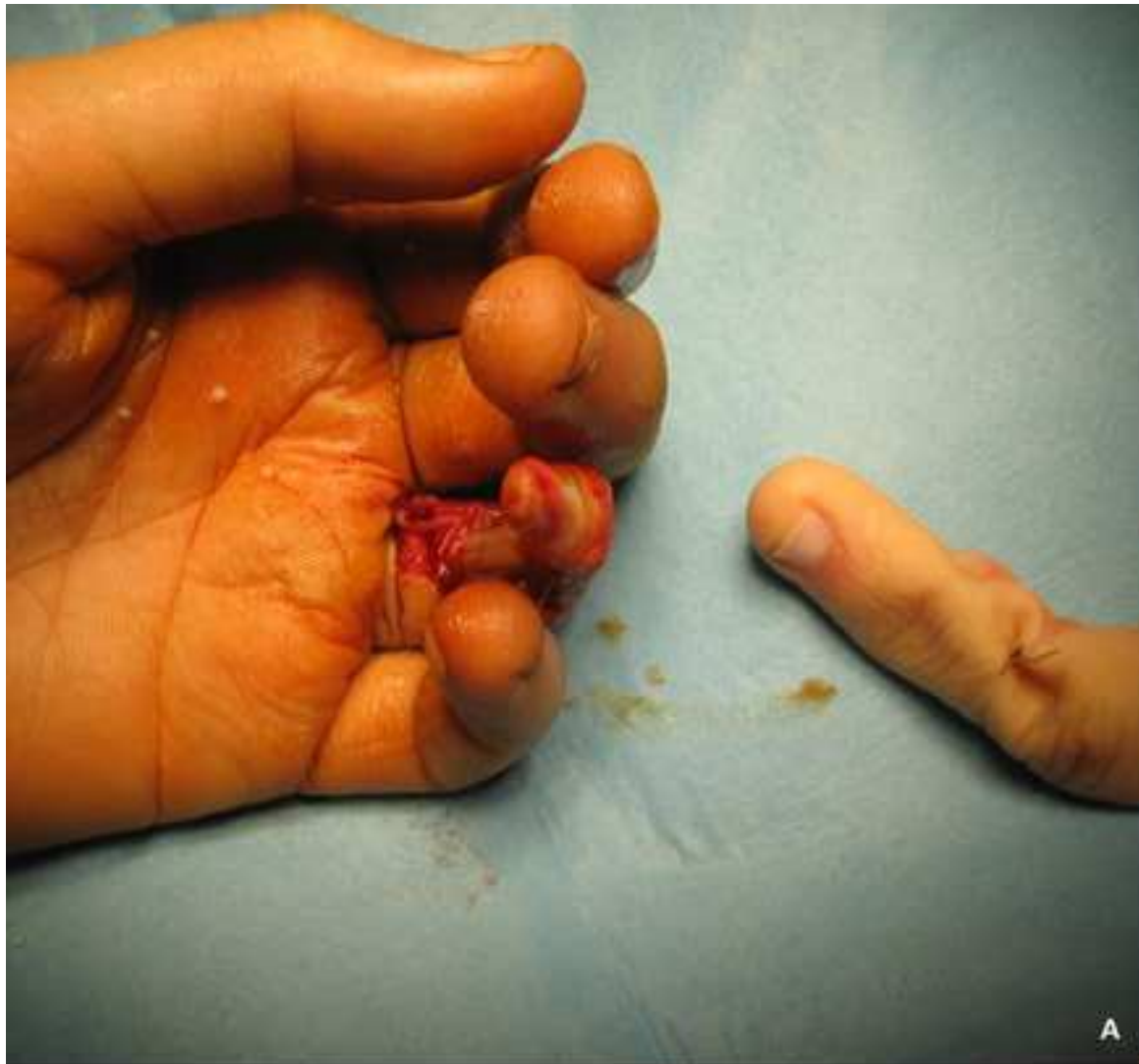D

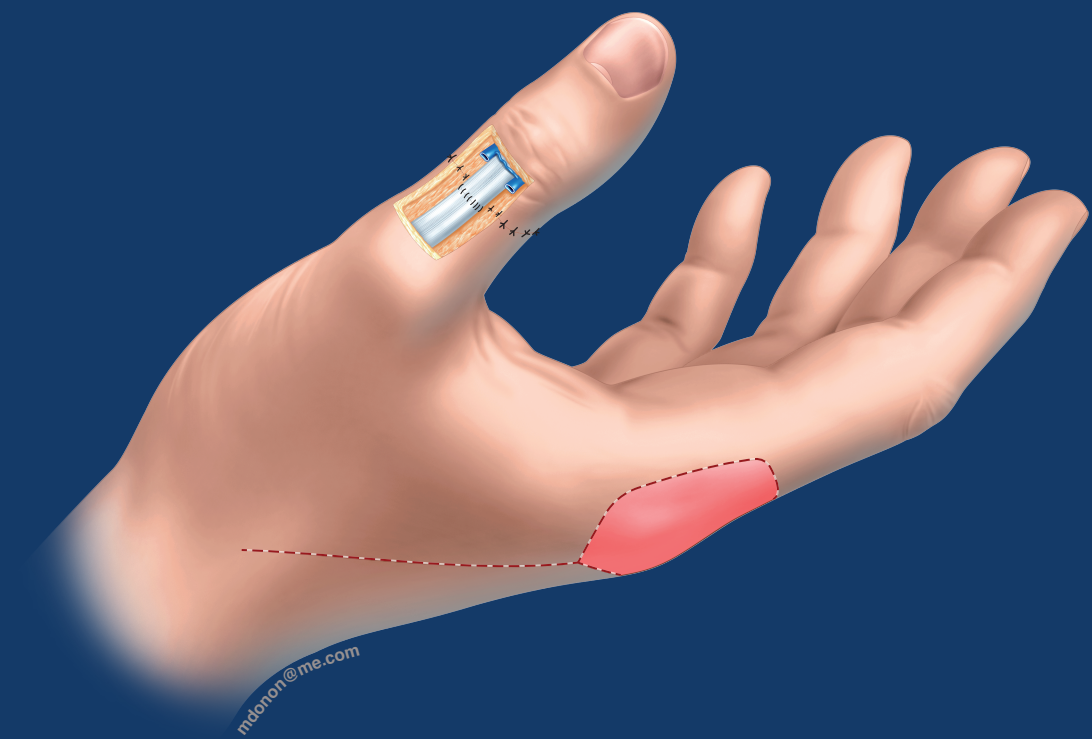


E

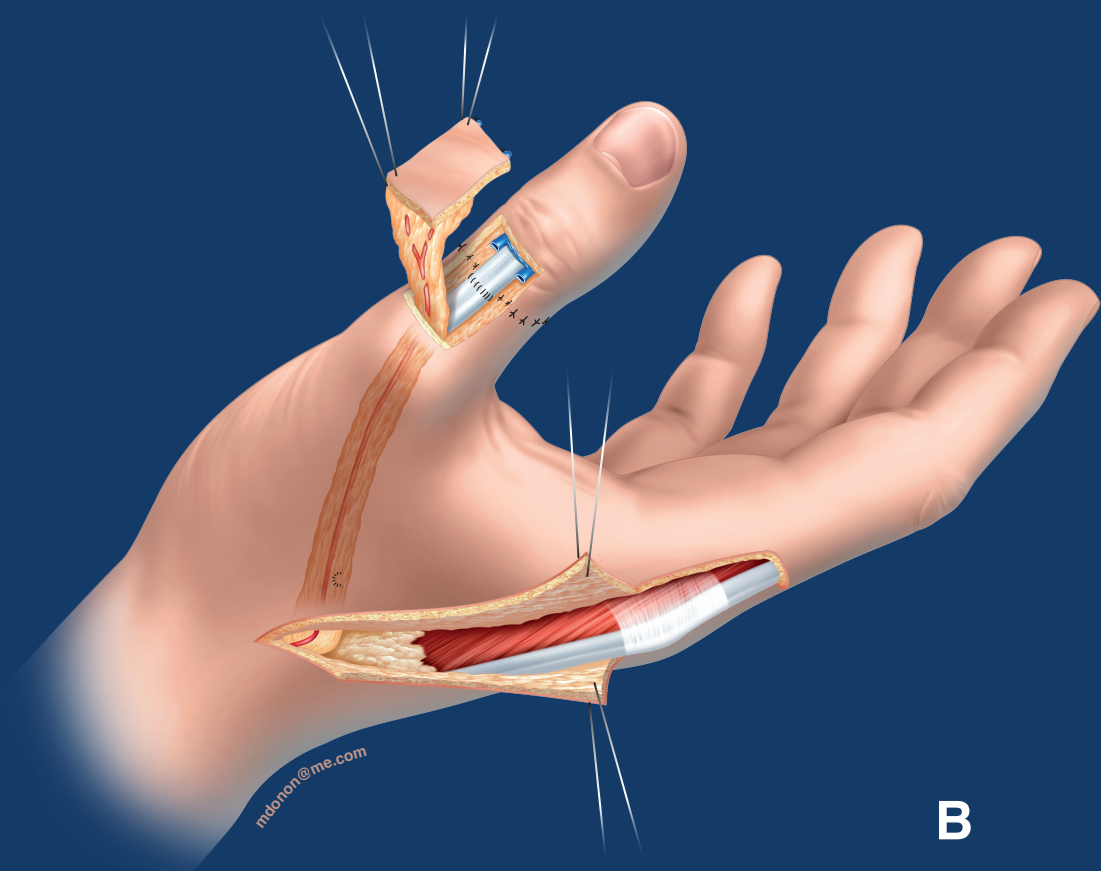


mcdonon@me.com

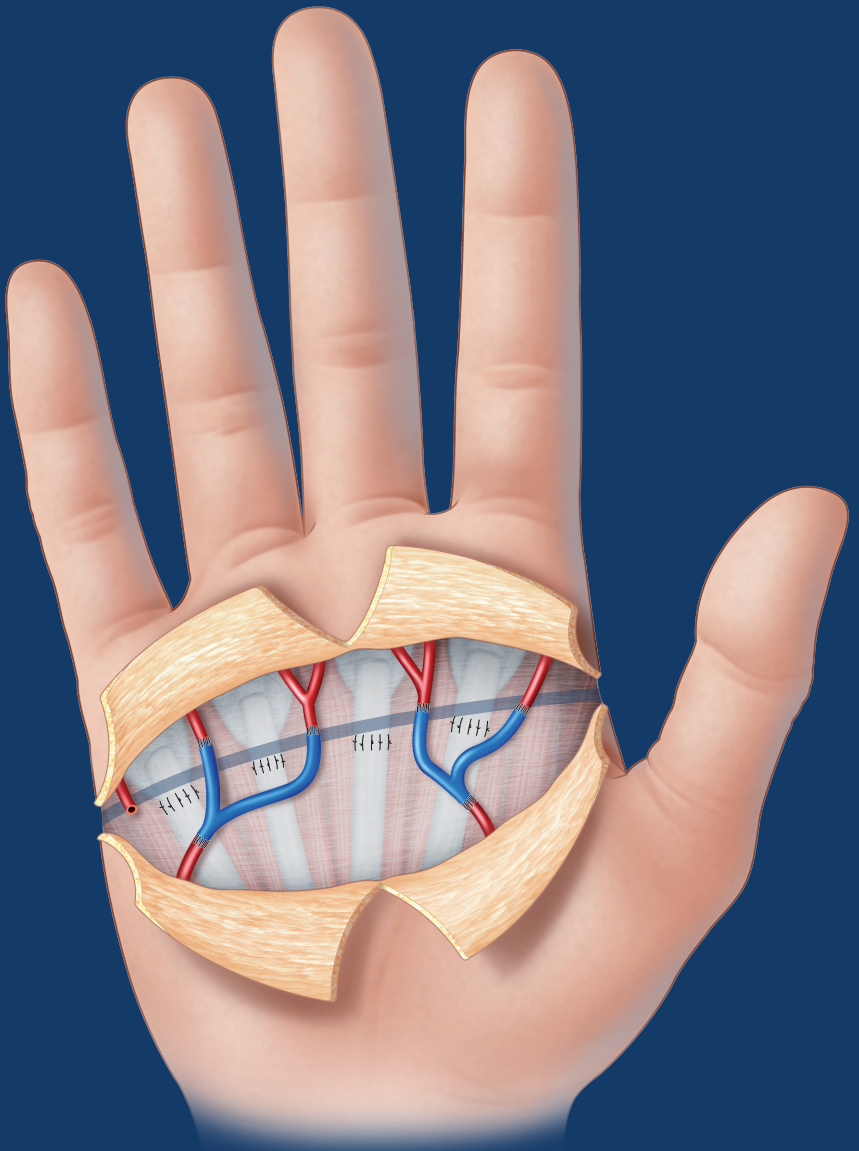




A



B



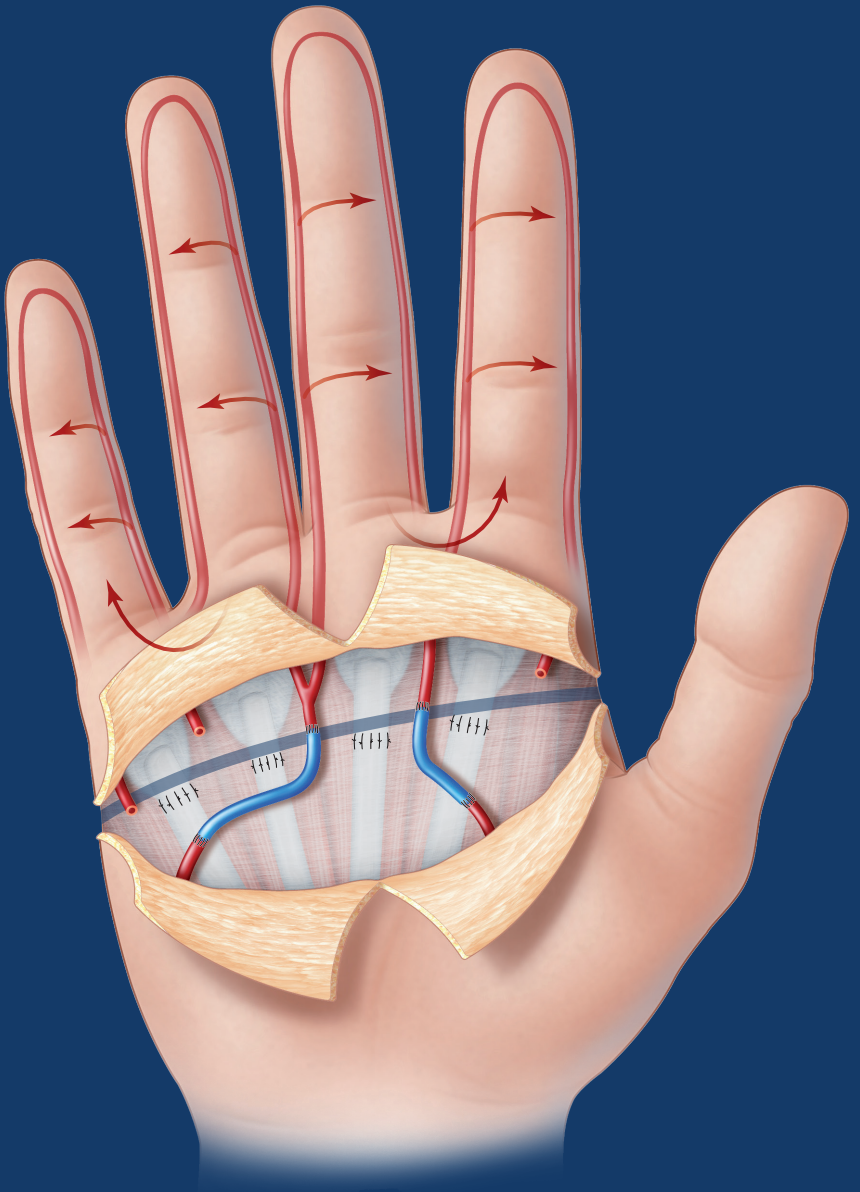
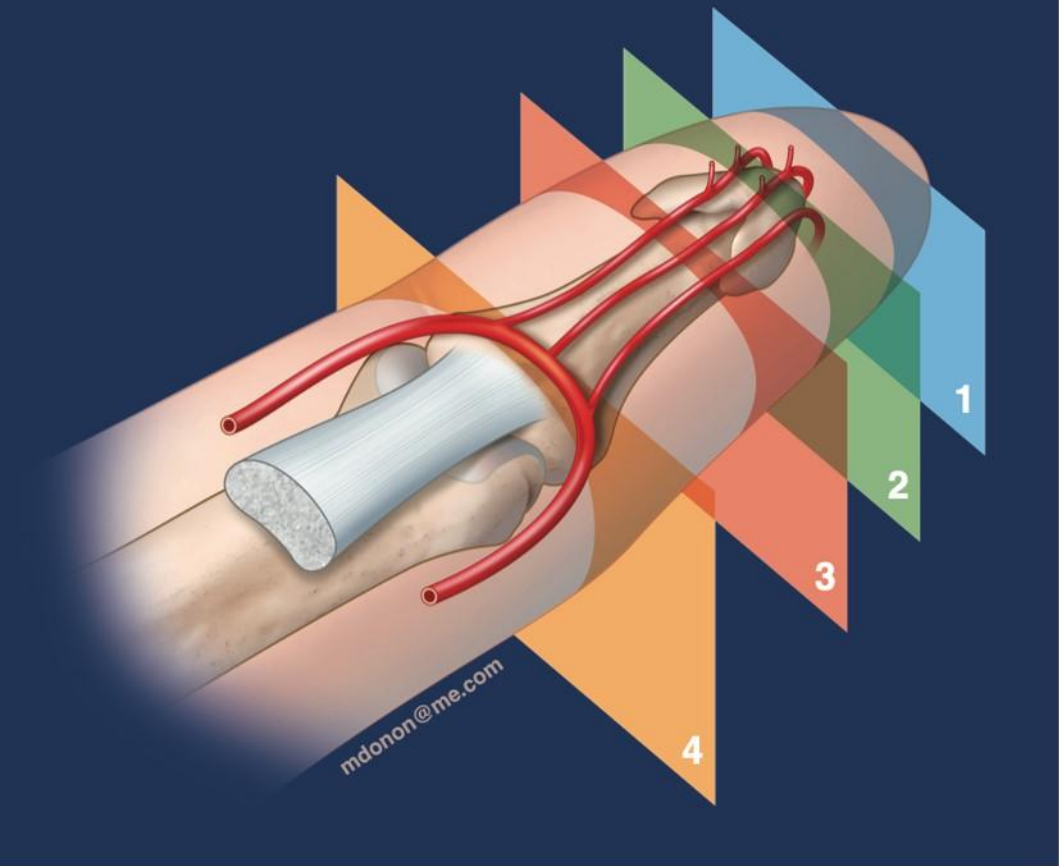


Figure 9



	Bone	Artery	Vein	Nerve
1	-	-	-	-
2	-	1	-	-
3	K wire	1	Dorsal/Palmar ^a	1 - 2
4	DIPJ fusion	1 - 2	Dorsal	2

^a Zhang [69] or Suzuki [65] technique can be considered; DIPJ: Distal Interphalangeal Joint

Table 1. Classification of ring finger injuries: Urbaniak [72] revised by Kay et al. [78] and subdivision of the class IV injuries according to Adani et al. [76]

Stage	Description
I	Circulation adequate with or without skeletal injury
II	Circulation inadequate, no skeletal injury
IIA	Arterial circulation inadequate only
IIB	Venous circulation inadequate only
III	Circulation inadequate with fracture or joint injury present
IIIA	Arterial circulation inadequate only
IIIB	Venous circulation inadequate only
IV	Complete amputation
IVd	Amputation distal to the FDS insertion
IVp	Amputation proximal to the FDS insertion

FDS: flexor digitorum superficialis

Table 2. Guide to efficiency and time saving in digit replantations

	Basic		Thumb Variation		Ring finger		Multi-digit and transmetacarpal
1	Osteosynthesis	1	Arterial graft on amputated part	1	Arterial graft on amputated part	1	Osteosynthesis
2	Extensor tendon repair	2	Osteosynthesis	2	Osteosynthesis	2	Extensor tendon repair
3	Flexor tendon repair	3	Proximal arterial anastomosis	3	Proximal arterial anastomosis	3	Vein repair/ Venous flap
4	Arterial repair/ reconstruction	4	Extensor tendon repair	4	Arterial repair/ reconstruction	4	Flexor tendon repair
5	Nerve repair/ reconstruction	5	Flexor tendon repair	5	Nerve repair or neurotization	5	Arterial repair/ reconstruction
6	Vein repair/ reconstruction	6	Nerve repair/ reconstruction	6	Vein repair/ Venous flap	6	Nerve repair/ reconstruction
7	Skin Closure	7	Vein repair/ Venous flap	7	Skin Closure	7	Skin Closure
8	Dressing and splint	8	Skin Closure	8	Dressing and splint	8	Dressing and splint
		9	Dressing and splint				

--- : with or without tourniquet

