



HAL
open science

Extensor indicis proprius tendon transfer using shear wave elastography

J. Lamouille, C. Müller, S. Aubry, Sabine F Bensamoun, W. Raffoul, S. Durand

► **To cite this version:**

J. Lamouille, C. Müller, S. Aubry, Sabine F Bensamoun, W. Raffoul, et al.. Extensor indicis proprius tendon transfer using shear wave elastography. *Hand Surgery and Rehabilitation*, 2017, 36 (3), pp.173-180. 10.1016/j.hansur.2017.02.001 . hal-03797983

HAL Id: hal-03797983

<https://utc.hal.science/hal-03797983v1>

Submitted on 24 Nov 2022

HAL is a multi-disciplinary open access archive for the deposit and dissemination of scientific research documents, whether they are published or not. The documents may come from teaching and research institutions in France or abroad, or from public or private research centers.

L'archive ouverte pluridisciplinaire **HAL**, est destinée au dépôt et à la diffusion de documents scientifiques de niveau recherche, publiés ou non, émanant des établissements d'enseignement et de recherche français ou étrangers, des laboratoires publics ou privés.

Extensor indicis proprius tendon transfer using shear wave elastography

Transfert tendineux de l'extensor indicis proprius sous élastographie par ondes de cisaillement

J. Lamouille^a, C. Müller^a, S. Aubry^b, S. Bensamoun^c, W. Raffoul^a, S. Durand^{a,*}

^aService de chirurgie plastique et de la main, département de l'appareil locomoteur, centre hospitalier universitaire vaudois (CHUV), rue du Bugnon 46, 1011 Lausanne, Switzerland

^bService d'imagerie ostéoarticulaire, hôpital Jean-Minjoz, 3 boulevard Fleming, 25030 Besançon cedex, France

^cUMR CNRS 7338, laboratoire de biomécanique et bioingénierie, Université de technologie de Compiègne, rue Roger-Coutolenc, 60200 Compiègne, France

Corresponding author

E-mail address: Sebastien.durand@chuv.ch (S. Durand).

ABSTRACT

The means for judging optimal tension during tendon transfers are approximate and not very quantifiable. The purpose of this study was to demonstrate the feasibility of quantitatively assessing muscular mechanical properties intraoperatively using ultrasound elastography (shear wave elastography [SWE]) during extensor indicis proprius (EIP) transfer. We report two cases of EIP transfer for post-traumatic rupture of the extensor pollicis longus muscle. Ultrasound acquisitions measured the elasticity modulus of the EIP muscle at different stages: rest, active extension, active extension against resistance, EIP section, distal passive traction of the tendon, after tendon transfer at rest and then during active extension. A preliminary analysis was conducted of the distribution of values for this modulus at the various transfer steps. Different shear wave velocity and elasticity modulus values were observed at the various transfer steps. The tension applied during the transfer seemed close to the resting tension if a traditional protocol were followed. The elasticity modulus varied by a factor of 37 between the active extension against resistance step (565.1 kPa) and after the tendon section (15.3 kPa). The elasticity modulus values were distributed in the same way for each patient. The therapeutic benefit of SWE elastography was studied for the first time in tendon transfers. Quantitative data on the elasticity modulus during this test may make it an effective means of improving intraoperative adjustments.

Keywords: Elastography Tendon transfer, Skeletal muscle mechanics, Wide-awake hand surgery.

RESUME

Les moyens de juger la tension optimale lors des transferts tendineux sont approximatifs et peu quantifiables. L'objectif de cette étude était de démontrer la faisabilité d'évaluer quantitativement les propriétés mécaniques musculaires en peropérateur par élastographie ultrasonore (shear wave elastography [SWE]) lors du transfert de l'extenseur indicis proprius (EIP). Nous rapportons deux cas de transfert de l'EIP pour rupture post-traumatique de l'extenseur pollicis longus. Des acquisitions ultrasonores ont mesuré le module d'élasticité du corps musculaire de l'EIP à différentes étapes : repos, extension active, extension active contre résistance, section de l'EIP, traction passive distale du tendon, après transfert tendineux au repos, puis en extension active. Une analyse préliminaire de la distribution des valeurs de ce module en fonction des étapes du transfert a été effectuée. Des valeurs différentes de la vitesse d'onde de cisaillement et du module d'élasticité ont été observées aux différentes étapes du transfert. La tension imposée au cours du transfert semblait proche de la tension de repos si l'on suivait un protocole classique. Le module d'élasticité variait d'un facteur 37 entre l'étape d'extension active contre résistance (565,1 kPa) et après section tendineuse (15,3 kPa). Les valeurs du module d'élasticité étaient distribuées de façon identique pour chaque patient. L'intérêt thérapeutique de l'élastographie SWE a été étudié pour la première fois dans les transferts tendineux. Les données quantitatives du module d'élasticité lors de cet examen feront possiblement de celui-ci un moyen efficace d'amélioration des réglages peropérateurs.

Mots clés : Elastographie, Transfert tendineux, Mécanismes musculosquelettiques, Chirurgie de la main éveillée

INTRODUCTION

Tendon transfers are used to reestablish a loss of function in spastic, quadriplegic patients, following an injury to the brachial plexus or peripheral nerves or even after a direct injury to the muscle or tendon [1]. Tendon transfers involve using the tendon of a functional muscle, sectioning it, and rerouting it to suture to another tendon or directly to the bone, ensuring that it performs the function that was lost as well as possible.

The surgeon must use several criteria to select the muscle to transfer:

- its functionality (innervated and non-traumatized);
- its synergy;
- its strength (proportional to the physiological cross sectional area [PCSA]);
- the length of its fibers [2].

The surgeon must also determine the path, the insertion (lever arm), and the tension applied to the transfer at the time of the surgery.

This last point is particularly important, because if the transfer tension is too light, the muscle will have no active or passive mechanical efficiency, and if the tension is too strong, the transfer will have only a tenodesis effect with no active strength. The surgeon chooses the passive tension he or she applies at the time of the transfer, based on the objectives (position of the joint at which the surgeon wants the maximum active strength and position of the joint at which the surgeon wants the maximum passive tension).

The principles used to judge passive tension based on the objective and length at which the muscle should be attached are subjective and approximate, which is why there needs to be quantifiable objective data on the transferred muscle.

In a study on transferring the flexor carpi ulnaris to the extensor of the fingers or wrist, it has been shown that, using traditional techniques, the tendons had a relatively high passive tension, which generated only 25% maximum active strength, which helps to explain why a loss of transferred muscle strength is traditionally observed in tendon transfers, amounting to one point on the “Medical Research Council of Great Britain” (MRC) muscle strength

grading scale [3]. Although it is possible to have some relaxation in a stretched muscle, it is difficult to count on this factor to optimize a tendon transfer [4].

Some authors have therefore proposed using a diffraction laser, which can estimate the length of the sarcomere intraoperatively in order to adjust the tension of the tendon transfer [3,5]. This piece of equipment, which is rarely used in clinical practice, can provide histomorphological information about the contractile component of the classical Hill model.

Shear wave elastography (SWE) is a recently developed method for determining the mechanical properties of soft tissue. This technique was first introduced in the early 1990s in vitro [6] and then gradually expanded into clinical practice for diagnostic and sometimes prognostic purposes in the fields of senology, hepatology, thyroid diseases, prostatic diseases, and musculoskeletal conditions [7–11]. This technique noninvasively measures the rigidity or elasticity of tissue by measuring the propagation speed of shear waves, resulting in mechanical disturbances of ultrasonic waves applied to the tissue by the ultrasound probe [12,13]. Ultrasound and SWE equipment, in widespread clinical use, can provide not only morphological data but also mechanical data pertaining to the overall muscular structure (contractile and elastic component) and can also dynamically record the muscle's kinetics. It is therefore possible to study the study the therapeutic benefit of elastography in tendon transfers.

The primary purpose of this study was to demonstrate the feasibility of the quantitative assessment of muscular mechanical properties intraoperatively using SWE elastography during extensor indicis proprius (EIP) transfer. The secondary purpose was to assess the accuracy of this test by analyzing the consistency of the observed values between two patients.

MATERIALS AND METHOD

This study included two patients (a 61-year-old male and a 70-year-old female) who presented with a complete section of the extensor pollicis longus (EPL) in zone T4 (opposite the first metacarpal). A transfer of the EIP to the EPL was performed in these two patients due to a failure of the primary repair. The approval of the ethics committee for this clinical case report was not required in our establishment.

The “wide awake surgery” anesthesia technique, described for the tendon transfer of the EIP to the EPL, was used in this study [14]. For each patient, a 27-gauge needle injection of 30 mL of lidocaine 1% with epinephrine 1:100,000, buffered with 3 mL of bicarbonate 8.4% was carried out once in the region of the index metacarpophalangeal joint (MP2) and the dorsal side of the first metacarpal and the wrist, allowing the patient to maintain his or her muscle function.

The procedure was carried out without a tourniquet. A distal section of the EIP opposite the second metacarpophalangeal joint was performed, and the tendon was retrieved proximally by means of a small transverse incision on the distal edge of the extensor retinaculum. The EIP was then tunneled subcutaneously to join up with a third incision in the area of the anatomical snuffbox. The EIP tendon was then sutured to the EPL according to the Pulvertaft technique, using a non-absorbable 3.0-braided polyethylene thread [15]. The transfer tension was chosen so that, when the wrist is in the neutral position, the thumb’s interphalangeal joint is spontaneously extended, and a passive pinch of the middle finger and thumb is possible.

The SWE measurements were taken using the same equipment (Aixplorer1, Aix-en-Provence, France), with a high-frequency SHL 15-4 probe (medium frequency 12 kHz), placed in a sterile cover with an abundant quantity of ultrasound gel. A first step using B-mode ultrasound made it possible to locate the EIP muscle in the distal third of the forearm and to place the ultrasound probe strictly parallel to the direction of the muscle fibers (Fig. 1).

A second step used the SWE elastography function in penetration mode. A mapping of the shear wave velocity, superimposed over the B-mode image, from blue (soft tissue, low speed) to red (hard tissue, high speed), produced the first qualitative information.

A 3 mm² Q-Box (quantitative box) focus area was established in the middle of the muscle, and the quantitative values were obtained in m/s (shear wave velocity) and in kPa (elasticity modulus).

For each patient, the quantitative measurements were performed at different stages of the transfer: at rest (R), during active extension (AE), active extension against resistance (AER), after section of the EIP tendon (S), during distal passive traction of the tendon (P) and then after a tendon transfer at rest (T), and then during active extension (TAE).

RESULTS

We were able to obtain intraoperative values at each transfer time for both patients. The SWE elastography added minimal additional procedure time due to the nearly instantaneous data acquisition speed and required a dedicated operator to record data, located outside of the surgical site.

The qualitative results, i.e. the color mapping, showed similar images for both patients at each recording step. At rest, the map was dark blue (soft tissue). Then, the color gradually changed to light blue (AE) and then in active extension against resistance to red (hard tissue) as the active contraction increased. After the section of the EIP tendon (S), the blue became intense and darker, and then it turned increasingly lighter with an appearance of yellow areas (intermediate rigid tissue) during passive tension (P). Finally, during the tendon suture, the color again became dark blue and lightened when the patient performed an active extension intraoperatively (Figs. 2-8).

The quantitative values for both patients at the different stages of the tendon transfer are shown in Table 1, which indicates that the elasticity modulus varied by a factor of 37 and the shear wave velocity varied by a factor of 6 between the muscle's maximum rest phase after the tendon section (S) and the maximum contraction phase (AER). Finally, there were relatively similar values between the two patients at each transfer stage (Fig. 9), except during active extension against resistance (AER).

The shear modulus values were identically distributed for each patient, which means that there was a sufficient difference in value at each transfer stage to obtain consistent distributions of values for each patient.

DISCUSSION

The propagation speed of the shear wave is related to the shear modulus of the tissue by the relationship: $m = \rho V_s^2$, where m is the tissue's shear modulus (kPa), ρ is the density of the muscle ($1000 \text{ kg}\cdot\text{m}^{-3}$), and V_s is the shear wave velocity ($\text{m}\cdot\text{s}^{-1}$).

Due to the anisotropy of the muscle tissue (different mechanical properties in each direction), there is no simple relationship between the shear modulus and Young's modulus (E), which is the most relevant measurement for studying the rigidity of tissue. It has been demonstrated, however, that when the ultrasound probe is placed parallel to the muscle fibers, there is a linear relationship

between the shear modulus (m) of the muscle and Young's

modulus (E), thereby making it possible to make a valid characterization of the rigidity of the muscle tissue: $E \approx 3 m$ [16].

This muscle shear modulus was measured during passive tension in the medial head of the gastrocnemius muscle in humans during a dorsiflexion movement of the ankle or on the tibialis anterior muscle during plantar flexion movement. The authors reported that there was a relationship between the shear modulus and the length of the muscle [17,18]. These results were confirmed in vitro on chicken muscles; there again, a strong linear relationship was shown between the shear modulus and passive muscle strength [19]. There is also a demonstrated relationship between the shear modulus and the active strength developed during isometric contraction by the tibialis anterior muscle at different degrees of dorsal flexion of the ankle [20]. There is therefore a demonstrated relationship between passive tension and the active strength of the muscle with the muscle's shear modulus and, by extension, Young's modulus.

Ultrasound elastography of the musculotendinous tissue has many potential indications, whose interest remains to be demonstrated, for the most part. The first elastosonography technique that was developed is quasi-static elastography (strain elastography), which semi-quantitatively studies the deformation of tissue submitted to an external stress (the probe). The more recent SWE elastography provides quantitative results that appear promising for accurately assessing musculotendinous pathologies. For example, SWE elastography has been used in Achilles tendinopathies, and it has been shown to be a sensitive and specific test for diagnostic purposes [11,21] and that there is a better correlation between the histology and elastography in comparison to the conventional B-mode (ultrasound) [22].

In lateral epicondylitis, quasi-static elastography is shown to be more effective for diagnosis than conventional B-mode ultrasound [23]. In trigger finger, it has been able to demonstrate an increase in the pulley A1 stiffness in patients relative to the control group. Three weeks after injecting corticosteroids, it was demonstrated that the trigger finger disappeared, and the rigidity of the pulley decreased [24].

As for the muscle tissue, the muscle at rest appears soft in the elastography, while the contracted muscle appears hard [25], and can thus be better detected for an injection of botulinum toxin in spastic patients [26]. In addition, elastography can be beneficial for diagnostic purposes in congenital muscular dystrophies [27] and in painful myofascial syndrome [28]. It is also possible that SWE elastography can provide information to better understand the healing process after muscle trauma [9] and can undoubtedly also be useful for diagnostic purposes in acute or chronic compartment syndrome. There are relatively few publications concerning the use of SWE elastography for the exploration of masses or tumors of musculoskeletal tissue. It seems that the rigidity of the lesions observed using elastography is less significant in nervous tumors, neuromas, and metastases compared to lipomas and vascular malformations [29]. This test can have diagnostic value and prevent some invasive

procedures. Finally, other indications have been described, still for diagnostic purposes, such as plantar fasciitis [30] and carpal tunnel syndrome [31].

The single use of clinical markers through the traditional guidelines leads to many failed tendon transfers [4]. The physiological explanation rests in part on the understanding of the Blix curve, which represents the strength-length ratio of the active muscle, i.e. when it is stimulated and generates tension, based on the length at which it is found [4]. There is an optimal muscle length corresponding to the maximum strength that the muscle can develop under isometric conditions. It is generally close to the length of the muscle at rest. It is the length where a maximum of actin/myosin bridges can be formed. A second strength-length ratio also exists. It corresponds to the resistance passively generated by the non-stimulated muscle when it is subjected to elongation. The increase is exponential due to the viscoelastic behavior of the muscle. This increase in passive tension is due to elastic proteins (titins) that attach to myofilaments of myosin with Z-lines. This strength is null below the optimal length and increases up to a maximum elongation that can support the sarcomere, beyond which the cytoskeleton ruptures. The sum of the two curves, active and passive tensions, provides the total tension that a muscle can produce based on the length at which it is stimulated. Depending on the length, the generated strength will involve the contractile component and/or the elastic component. If the length of the sarcomere at rest is short, at a given tension, it may approach the optimal length. However, if its length at rest is long, at the same passive tension, it will be beyond the optimal zone, and the result of the transfer will be poor.

The muscles of the arm have a sarcomere length at rest that

varies from 2.5 to 3.5 mm. The factors influencing this length are little known and use only tension as a criterion, leading to excessive stretching and diminished active strength [3].

In addition, the attitude of using only morphological data (sarcomere length) from the contractile component of the Hill model to adjust the tendon transfer is attractive, but it does not account for connective tissue (elastic component) limiting excursion, the mechanism of some muscles [1].

Intraoperative SWE ultrasound has proven to be a quick and easy test to perform by simply applying the ultrasound probe to the skin, without requiring direct contact with the muscle, unlike the use of a diffraction laser. It can therefore be adapted also to the deepest muscles in the hand. The ease of execution, speed, and simplicity of SWE measurements in musculoskeletal applications have been demonstrated on the calcaneal tendon [32] and on muscle tissue [33]. In our study, the surgical time was only slightly increased (5 to 10 minutes), and therefore it is perfectly usable during a surgical procedure.

SWE elastography makes it possible to assess overall muscle rigidity, which is influenced by the contractile and elastic component in parallel to the classical Hill model. Regardless of the size of the sarcomere at rest or the passive tension that is applied, SWE elastography provides objective data on the rigidity of the muscle as a whole. We have been able to demonstrate, both qualitatively and quantitatively, a notable difference in muscle rigidity at all the different stages of tendon transfer, with scale of the shear wave velocity and elasticity modulus varying by a factor of 6 and 37, respectively. The distribution of values was consistent for both patients at each stage of the transfer. For active extension against resistance, there was a notable difference that was possibly related to the difference in sex and age, as well as symptomatic rhizarthrosis in the patient with the lower elasticity modulus. Finally, the elasticity modulus of the muscle at rest after transfer seems close to the elasticity modulus before transfer.

This feasibility study is the first study to quantitatively show notable differences in the elasticity modulus based on the loading conditions of the muscle at the various stages of a tendon transfer surgical procedure.

We believe that there are probably specific elasticity modulus values that should be applied to the muscle during a tendon transfer in order to ensure the best possible clinical result. The objective data provided by this test possibly has a broad therapeutic interest in addressing tension in tendon transfer, because the clinical data has serious limitations. It can also help us better understand the success and failure mechanisms of tendon transfer through intraoperative and postoperative measurements. Yet, this test is technically demanding and highly sensitive to the quality of the protocol that has been put into place.

A future study with a larger population, a standardized protocol, and a longer term follow-up will be necessary in order to compare the clinical results based on SWE elastography data, as it could become an additional tool in optimizing tendon transfers.

DISCLOSURE OF INTEREST

The authors declare that they have no competing interest.

REFERENCES

- [1] Frida J, Lieber RL. Mechanical considerations in the design of surgical reconstructive procedures. *J Biomech* 2002;35:1039–45.
- [2] Lieber RL. Skeletal muscle architecture: implications for muscle function and surgical tendon transfer. *J Hand Ther* 1993;6:105–13.
- [3] Friden J, Lieber RL. Tendon transfer: clinical implications of experimental studies. *Clin Orthop Relat Res* 2002;403(Suppl.):S163–70.
- [4] Friden J, Lieber RL. Evidence for muscle attachment at relatively long lengths in tendon transfer surgery. *J Hand Surg Am* 1998;23:105–10.
- [5] Lieber R, Loren G, Friden J. In vivo measurement of human wrist extensor muscle sarcomere length changes. *J Neurophysiol* 1994;71:874–81.
- [6] Ophir J, Cespedes I, Ponnekanti H, Yazdi Y, Li X. Elastography: a quantitative method for imaging the elasticity of biological tissues. *Ultrason Imaging* 1991;13:111–34.
- [7] Debernard L, Robert L, Charleux F, Bensamoun SF. Characterization of muscle architecture in children and adults using magnetic resonance elastography and ultrasound techniques. *J Biomech* 2011;44:397–401.
- [8] Drakonaki EE, Allen GM, Wilson DJ. Ultrasound elastography for musculoskeletal applications. *Br J Radiol* 2012;85:1435–45.
- [9] Klauser AS, Miyamoto H, Bellmann-Weiler R, Feuchtner GM, Wick MC, Jaschke WR. Sonoelastography: musculoskeletal applications. *Radiology* 2014;272:622–33.
- [10] Kim SJ, Park HJ, Lee SY. Usefulness of strain elastography of the musculoskeletal system. *Ultrasonography* 2016;35:104–9.

- [11] Aubry S, Nueffer JP, Tanter M, Becce F, Vidal C, Michel F. Viscoelasticity in Achilles tendinopathy: quantitative assessment by using real-time shear-wave elastography. *Radiology* 2015;274:821–9.
- [12] Bercoff J, Tanter M, Fink M. Supersonic shear imaging: a new technique for soft tissue elasticity mapping. *IEEE Trans Ultrason Ferroelectr Freq Control* 2004;51:396–409.
- [13] Hug F, Tucker K, Gennisson JL, Tanter M, Nordez A. Elastography for muscle biomechanics: toward the estimation of individual muscle force. *Exerc Sport Sci Rev* 2015;43:125–33.
- [14] Lalonde DH. Wide-awake extensor indicis proprius to extensor pollicis longus tendon transfer. *J Hand Surg Am* 2014;39:2297–9.
- [15] Pulvertaft RG. Tendon grafts for flexor tendon injuries in the fingers and thumb; a study technique and results. *J Bone Joint Surg Br* 1956;38:175–94.
- [16] Eby SF, Song P, Chen S, Chen Q, Greenleaf JF, An KN. Validation of shear wave elastography in skeletal muscle. *J Biomech* 2013;46:2381–7.
- [17] Koo TK, Guo JY, Cohen JH, Parker KJ. Quantifying the passive stretching response of human tibialis anterior muscle using shear wave elastography. *Clin Biomech* 2014;29:33-9.
- [18] Maïsetti O, Hug F, Bouillard K, Nordez A. Characterization of passive elastic properties of the human medial gastrocnemius muscle belly using supersonic shear imaging. *J Biomech* 2012;45:978–84.
- [19] Koo TK, Guo JY, Cohen JH, Parker KJ. Relationship between shear elastic modulus and passive muscle force: an ex-vivo study. *J Biomech* 2013;46:2053–9.

- [20] Sasaki K, Toyama S, Ishii N. Length-force characteristics of in vivo human muscle reflected by supersonic shear imaging. *J Appl Physiol* 2014;117:153–62.
- [21] Dirrichs T, Quack V, Gatz M, Tingart M, Kuhl CK, Schradling S. Shear wave elastography (SWE) for the evaluation of patients with tendinopathies. *Acad Radiol* 2016;23:1204–13.
- [22] Klauser AS, Miyamoto H, Tamegger M, Faschingbauer R, Moriggl B, et al. Achilles tendon assessed with sonoelastography: histologic agreement. *Radiology* 2013;267:837–42.
- [23] De Zordo T De, Lill SR, Fink C, Feuchtner GM, Jaschke W, et al. Real-time sonoelastography of lateral epicondylitis: comparison of findings between patients and healthy volunteers. *Am J Roentgenol* 2009;193:180–5.
- [24] Miyamoto H, Miura T, Isayama H, Masuzaki R, Koike K, Ohe T. Stiffness of the first annular pulley in normal and trigger fingers. *J Hand Surg Am* 2011;36:1486–91.
- [25] Debernard L, Robert L, Charleux F, Bensamoun S. Analysis of thigh muscle stiffness from childhood to adulthood using magnetic resonance elastography (MRE) technique. *Clin Biomech* 2011;26:836–40.
- [26] Vasilescu D, Vasilescu D, Ducea S, Botar-jid C, Sfra[^]ngeu S, Cosma D. Sonoelastography contribution in cerebral palsy spasticity treatment assessment, preliminary report: a systematic review of the literature apropos of seven patients. *Med Ultrason* 2010;12:306–10.
- [27] Drakonaki EE, Allen GM. Magnetic resonance imaging, ultrasound and real-time ultrasound elastography of the thigh muscles in congenital muscle dystrophy. *Skeletal Radiol* 2010;39:391–6.

- [28] Shankar H, Reddy S. Two- and three-dimensional ultrasound imaging to facilitate detection and targeting of taut bands in myofascial pain syndrome. *Pain Med* 2012;13:971–5.
- [29] Bhatia KSS, Rasalkar DD, Lee YP, Wong KT, King AD, et al. Real-time qualitative ultrasound elastography of miscellaneous non-nodal neck masses: applications and limitations. *Ultrasound Med Biol* 2010;36:1644–52.
- [30] Wu CH, Chang KV, Mio S, Chen WS, Wang TG. Sonoelastography of the plantar fascia. *Radiology* 2011;259:502–7.
- [31] Miyamoto H, Miura T, Morizaki Y, Uehara K, Ohe T, Tanaka S. Comparative study on the stiffness of transverse carpal ligament between normal subjects and carpal tunnel syndrome patients. *Hand Surg* 2013;18:209–14.
- [32] Aubry S, Risson JR, Barbier-Brion B, Tatu L, Vidal C, Kastler B. Transient elastography of calcaneal tendon: preliminary results and future prospects. *J Radiol* 2011;92:421–7.
- [33] Lacourpaille L, Hug F, Bouillard K, Hogrel JY, Nordez A. Supersonic shear imaging provides a reliable measurement of resting muscle shear elastic modulus. *Physiol Meas* 2012;33:N19–28.

FIGURES

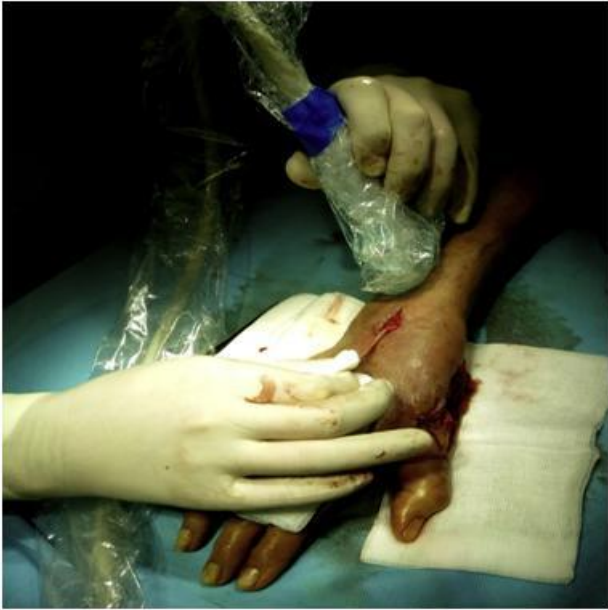

Fig. 1. Probe used for the SWE elastography placed parallel to the direction of the EIP’s fibers in contact with the skin and opposite the muscle. Passive traction of the EIP’s tendon and quantitative measurement of the shear wave velocity and elasticity modulus.

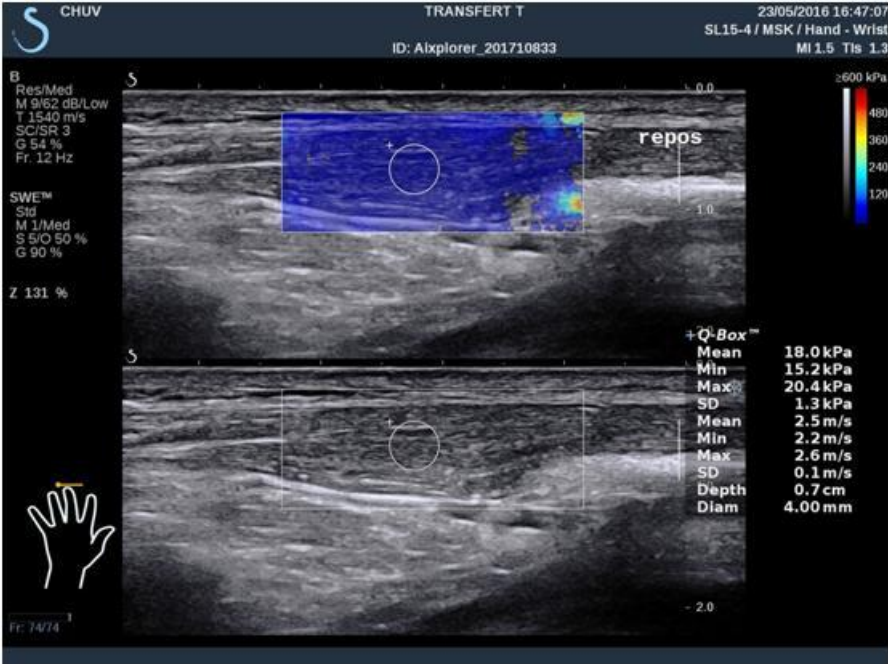


Fig. 2. B-mode ultrasound (low) and elastographic (high) recording during the 1st stage of the transfer (R).

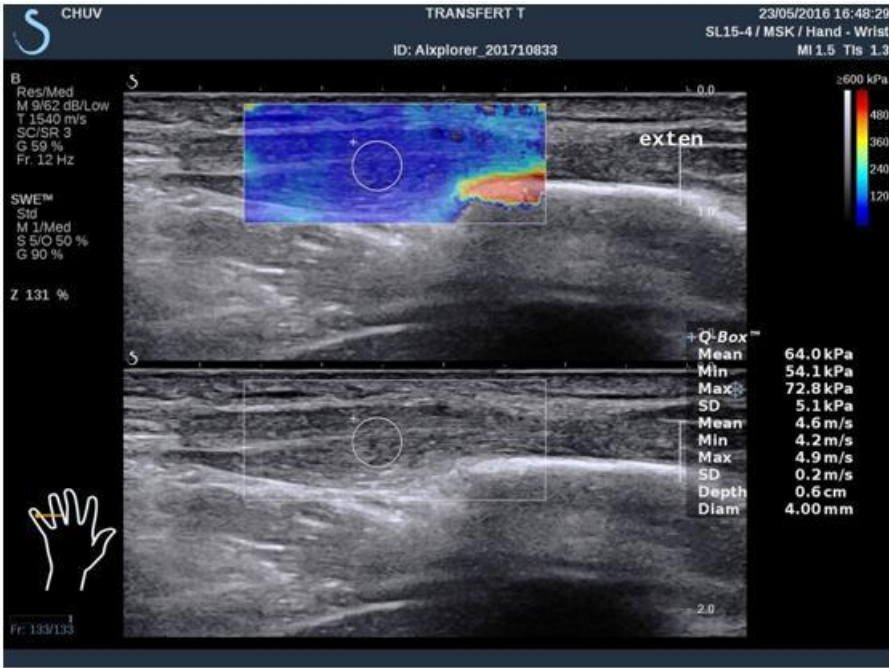


Fig. 3. B-mode ultrasound (low) and elastographic (high) recording during the 2nd stage of the transfer (AE).

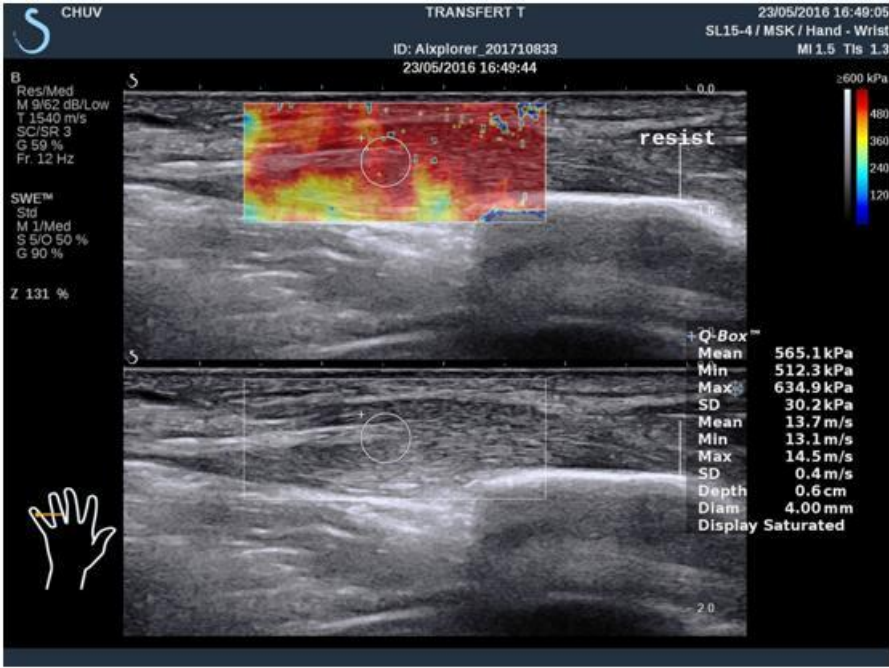


Fig. 4. B-mode ultrasound (low) and elastographic (high) recording during the 3rd stage of the transfer (AER).

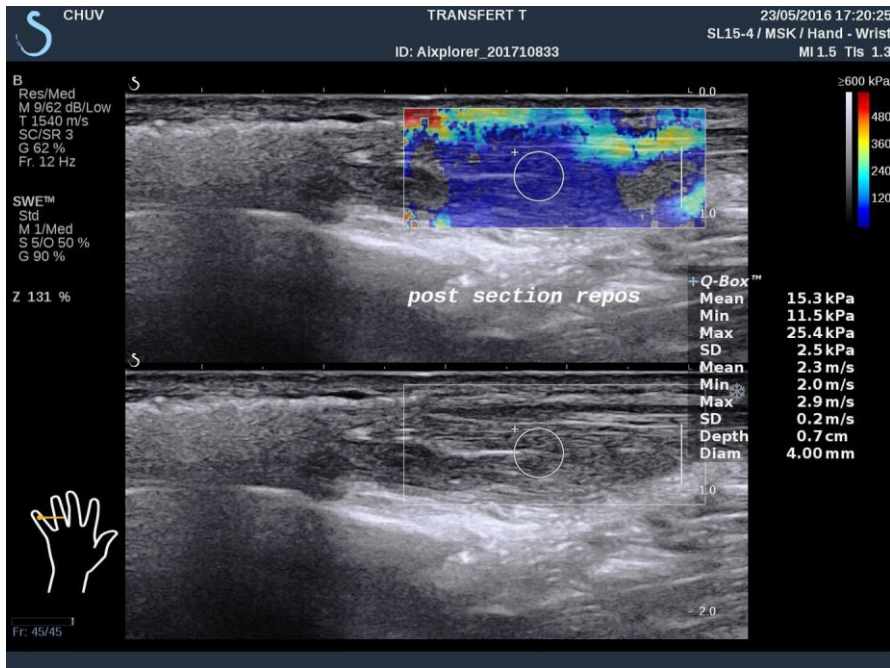


Fig. 5. B-mode ultrasound (low) and elastographic (high) recording during the 4th stage of the transfer (S).

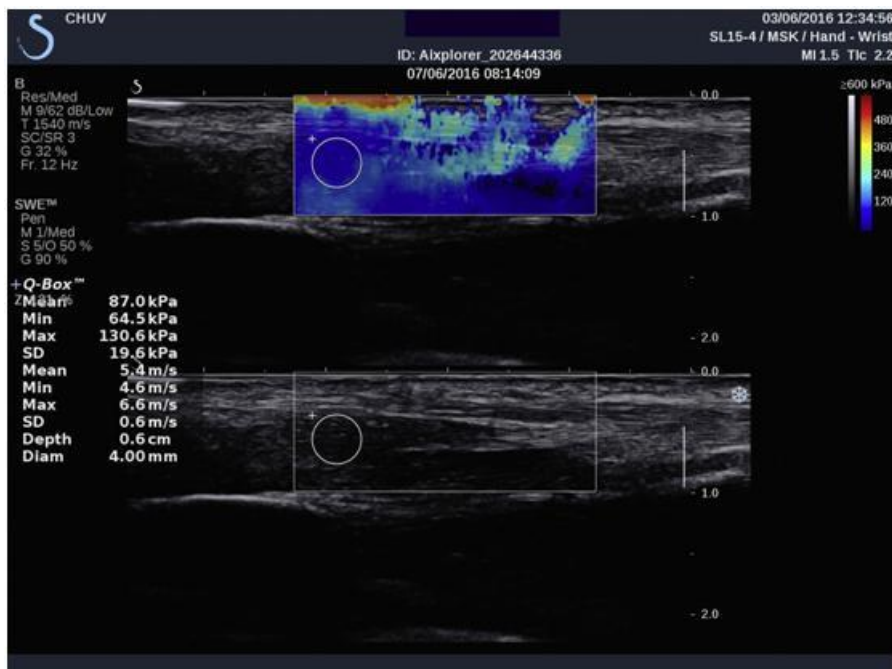


Fig. 6. B-mode ultrasound (low) and elastographic (high) recording during the 5th stage of the transfer (P).

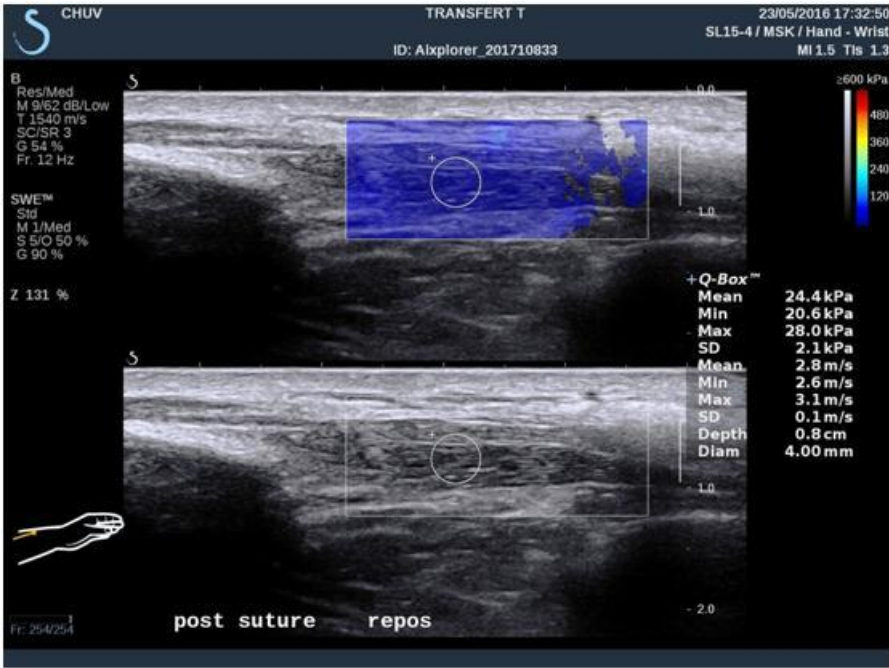


Fig. 7. B-mode ultrasound (low) and elastographic (high) recording during the 6th stage of the transfer (T).

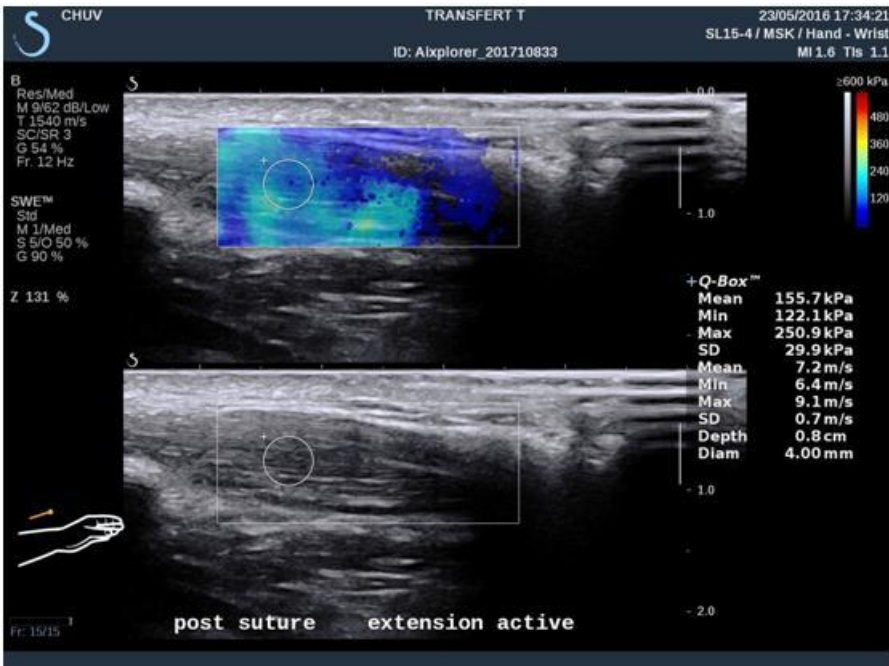


Fig. 8. B-mode ultrasound (low) and elastographic (high) recording during the 6th stage of the transfer (TAE).

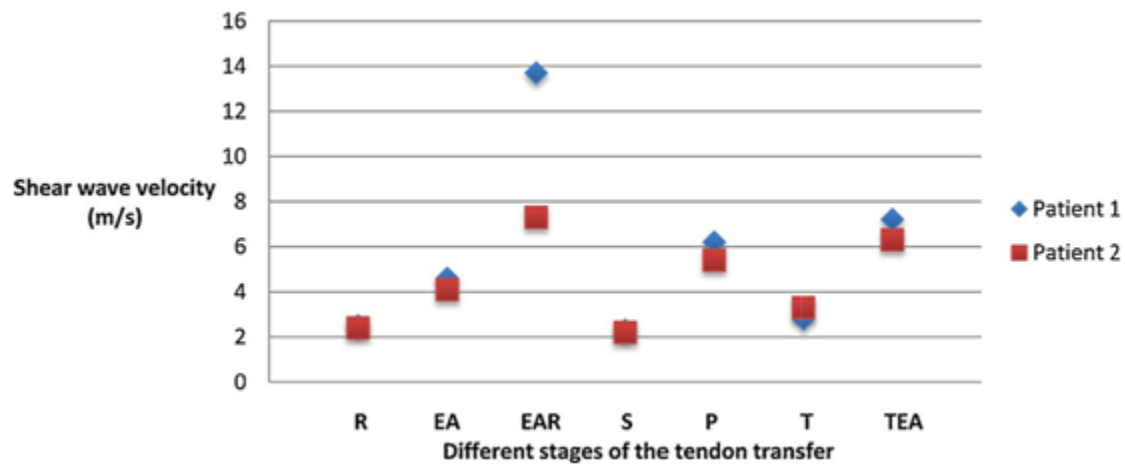


Fig. 9. Graph comparing the shear wave velocity of the two patients at each stage of the tendon transfer.

TABLE

Table 1

Results of the average elastographic data (SD).

	Patient 1		Patient 2	
	V (m/s)	E (kpa)	V (m/s)	E (kpa)
R	2.5 (0.1)	18 (1.3)	2.4 (0.3)	17.9 (3.2)
EA	4.6 (0.2)	64 (5.1)	4.1 (0.5)	51.9 (10.8)
EAR	13.7 (0.4)	565.1 (30.2)	7.3 (0.8)	160.7 (36.1)
S	2.3 (0.2)	15.3 (2.5)	2.2 (0.2)	14.2 (3.1)
P	6.2 (0.1)	116.2 (2.2)	5.4 (0.6)	87 (19.6)
T	2.8 (0.1)	24.4 (2.1)	3.3 (0.2)	33 (3.6)
TEA	7.2 (0.7)	155.7 (29.9)	6.3 (0.5)	118.7 (19.6)

R: rest before tendon section; AE: active extension before tendon section; AER: active extension against resistance before tendon section; S: rest after tendon