



HAL
open science

Cutoff Values for Alcoholic Liver Fibrosis Using Magnetic Resonance Elastography Technique

Sabine F Bensamoun, Gwladys E Leclerc, Laëticia Debernard, Xiaobin Cheng,
Ludovic Robert, Fabrice Charleux, Colette Rhein, Jean-Paul Latrive

► **To cite this version:**

Sabine F Bensamoun, Gwladys E Leclerc, Laëticia Debernard, Xiaobin Cheng, Ludovic Robert, et al.. Cutoff Values for Alcoholic Liver Fibrosis Using Magnetic Resonance Elastography Technique. *Alcoholism: Clinical and Experimental Research*, 2012, 37, pp.811 - 817. 10.1111/acer.12025 . hal-03811226v1

HAL Id: hal-03811226

<https://utc.hal.science/hal-03811226v1>

Submitted on 11 Oct 2022 (v1), last revised 12 Oct 2022 (v2)

HAL is a multi-disciplinary open access archive for the deposit and dissemination of scientific research documents, whether they are published or not. The documents may come from teaching and research institutions in France or abroad, or from public or private research centers.

L'archive ouverte pluridisciplinaire **HAL**, est destinée au dépôt et à la diffusion de documents scientifiques de niveau recherche, publiés ou non, émanant des établissements d'enseignement et de recherche français ou étrangers, des laboratoires publics ou privés.

Cutoff Values for Alcoholic Liver Fibrosis Using Magnetic Resonance Elastography Technique

Sabine F. Bensamoun, Gwladys E. Leclerc, Laëticia Debernard, Xiaobin Cheng, Ludovic Robert, Fabrice Charleux, Colette Rhein, and Jean-Paul Latrive

Background: Due to the lack of cutoff values validated for specific liver diseases, the purpose of this study was to set up specific magnetic resonance elastography (MRE) cutoff values for asymptomatic liver fibrosis in alcoholic patients.

Methods: Ninety patients underwent 3 clinical exams. The liver stiffness was measured locally with the Fibroscan, and globally through cartographies of shear modulus generated with MRE. The Fibroscan method was chosen as the gold standard to classify the fibrosis. The liver score was also obtained with the Fibrometer A, and the diagnostic performance of the methods was analyzed with receiver-operating characteristic (ROC) curves and cutoff values were calculated.

Results: Spearman correlation and area under the ROC curve revealed that MRE is a better diagnostic method than the Fibrometer A, to identify various levels of fibrosis. The results showed that the Fibrometer A was adapted for severe fibrosis. The MRE cutoff values are F1:2.20 kPa, F2:2.57 kPa, F3:3.31 kPa, and F4:4 kPa and were not influenced by the glutamic oxaloacetic transaminase level. By using the ultrasound cutoff values attributed for alcoholism, 66% of patients had a similar liver fibrosis diagnosis as the MRE cutoffs. However, both imaging techniques did not provide the same distribution for minor fibrosis.

Conclusions: None of the imaging techniques (Fibroscan, MRE) could replace the gold standard of the biopsy. However, due to the risk and the unnecessary procedure for the present recruited alcoholic patients, the Fibroscan method was chosen as the reference. Since MRE is currently being used as a clinical exam, the present MRE cutoffs could aid clinicians with their diagnosis of liver fibrosis for alcoholism disease.

Key Words: Alcoholic Liver Stiffness, Magnetic Resonance Elastography, Fibroscan, Cutoffs.

ALCOHOLISM DISEASE CONCERNS more and more people and becomes a major public healthcare problem with a relevant social and economical impact. Alcohol is the main cause of chronic liver disease, which may end up to cirrhosis, and new treatments such as baclofen are clinically test to fight this addiction (Paille, 2011).

To determine the stage of the liver fibrosis, biopsies have remained the gold standard. However, due to the invasive process and the risk incurred by the patients for the small harvested liver sample, other biochemical tests (Fibrotest, Fibrometer A) and imaging techniques (ultrasound and magnetic resonance elastography [MRE]) have been devel-

oped to estimate the liver stiffness. Alcoholic liver disease (ALD) presents various clinical settings (Mathurin, 2012; Mueller and Sandrin, 2010) such as inflammation (Arena et al., 2008; Mueller et al., 2010; Sagir et al., 2008), cholestasis, and venous pressure (Millonig et al., 2008), which could influence the liver stiffness.

Serum markers such as Fibrotest and Fibrometer A are accurately able to identify high-level stages of liver fibrosis or cirrhosis, but are not accurate with regard to identifying intermediate levels of liver fibrosis (Morra et al., 2008; Rockey and Bissell, 2006). Moreover, Naveau and colleagues (2009) showed that the Fibrometer A, which is specific for ALD, provided similar results as the Fibrotest.

In a way to better depict the intermediate liver stages and to avoid invasive procedures, elastography techniques have been used to assess the liver stiffness. Thus, the transient elastography (TE) method was used for alcoholic patients (Nahon et al., 2008; Trabut et al., 2012), and Gelsi and colleagues (2011) found changes in liver stiffness according to the consumption or the cessation of alcohol, suggesting the usefulness of the TE to follow the consequence of this pathology. TE was therefore extensively applied for the measurement of liver fibrosis stiffness, and Janssens and colleagues (2010) have analyzed the influence of the cutoff values, previously validated for chronic hepatitis C, on liver

From the Biomechanics and Bioengineering Laboratory (SFB, GEL, LD, XC), UMR CNRS 7338, UTC, Compiègne, France; ACRIM-Poly-clinique Saint Côme (LR, FC), Compiègne, France; Unité d'alcoologie (CR), CH Compiègne, Compiègne, France; and Service gastro-entérologie et hépatologie (J-PL), CH Compiègne, Compiègne, France.

Received for publication April 25, 2012; accepted September 4, 2012.

Reprint requests: Sabine Bensamoun, PhD, Laboratoire de Biomécanique et Bioingénierie, Université de Technologie de Compiègne (UTC), Centre de Recherches de Royallieu, UMR CNRS 7338, BP 20529, Rue Personne de Roberval, 60205 Compiègne Cedex, France; Tel.: 33 3 44 23 43 90; E-mail: sabine.bensamoun@utc.fr

Copyright © 2012 by the Research Society on Alcoholism.

DOI: 10.1111/acer.12025

stiffness classification for other etiologies such as alcoholism. It was concluded that these cutoffs were able to predict severe fibrosis ($\geq F3$) for alcoholic patients. In the literature, only Nguyen-Khac and colleagues had set up all of the intermediate cutoff values for asymptomatic liver fibrosis in alcoholic patients using the Fibroscan technique (Arena et al., 2008; Nguyen-Khac et al., 2008). It should be noted that these cutoffs are now used in clinical practice for alcoholic patients, but ultrasound elastography techniques are difficult to use accurately on obese patients and on persons exhibiting a narrow rib interspace (Nguyen and Talwalkar, 2011).

MRE, which is not limited by these factors (obesity, ascite, rib space), allows for a more global characterization of liver stiffness compared with the local measurements performed using ultrasound elastography techniques (Bensamoun et al., 2008). However, MRE results can also be altered by other criteria such as severe hepatic iron and portal hypertension, and it therefore remains a more restrictive method, which can be performed at the same time as a magnetic resonance imaging (MRI) test (Siegel, 2011). The MRE technique has been applied to patients with chronic liver disease, and Huwart and colleagues (2007, 2008) showed that it more accurately depicts liver fibrosis staging compared with biochemical tests and ultrasound elastography. Recently, Shire and colleagues (2011) performed a study focused only on the repeatability of the MRE technique to estimate the liver stiffness and have demonstrated the reproducible behavior of MRE to assess liver stiffness in hepatitis C virus patients and its capability to differentiate moderate fibrosis ($\geq F2$) from that of healthy liver. The cutoff values, for the MRE technique, were determined for different liver etiologies such as chronic hepatitis C and B, alcohol abuse, autoimmune disease, $\alpha 1$ -antitrypsin deficiency among others (Huwart et al., 2007). To our knowledge, no MRE studies have proposed cutoff values for specific liver diseases. Due to the lack of cutoff values, the purpose of this study was to set up specific MRE cutoff values for asymptomatic liver fibrosis in alcoholic patients using Nguyen-Khac and colleagues cutoff data base (Arena et al., 2008; Nguyen-Khac et al., 2008), defined specifically for alcoholic patients using the Fibroscan, as the reference. Obviously, none of the imaging techniques could replace the gold standard of the biopsy, even though biopsy may also provide an error and may not be representative of the entire liver volume. However, due to the risk of this invasive exam for the patients, and the unnecessary procedure for the present recruited alcoholic patients, the Fibroscan method was chosen as the gold standard (Kircheis et al., 2012). Subsequently, the diagnostic performance of the MRE technique was compared to the Fibroscan and Fibrometer A.

MATERIALS AND METHODS

Patients

Ninety patients (68 men and 22 women, mean age: 44.7 years, mean body mass index: body mass index = 23.8 ± 3.9 kg/m²) cur-

rently enrolled in alcohol dependence programs were recruited from 2009 to 2012 at the alcoholism department. Patients were hospitalized for 3 weeks for purposes of detoxification and to ensure that they followed a specific program for rehabilitation. During the first week, all patients underwent a blood test and the level of transaminase was analyzed (glutamic oxaloacetic transaminase [GOT] = 83.2 ± 88.8 U/l, glutamic pyruvic transaminase: 70.9 ± 72.5 U/l, gamma-glutamyltransferase: 448.9 ± 780.5 U/l, alkaline phosphatase: 97.3 ± 82.4 U/l). During the second week, a Fibroscan exam was performed and patients satisfying the following exclusion criteria claustrophobia, mental instability, existence of hepatitis, suspicion of hemochromatosis (coefficient of saturation $>45\%$), and invalidated Fibroscan test were selected for an MRE, and Fibrometer A tests performed only few days after the Fibroscan. The study was approved by the Institutional Review Board, and written informed consent was obtained.

Classification of the Liver Fibrosis Staging Using Fibroscan

The experimental setup was designed similar to Bensamoun and colleagues' study, who compared liver stiffness as measured by 2 different imaging techniques (Fibroscan and MRE), and is briefly summarized here. During the Fibroscan experiment, the subjects laid down with the right arm in maximal abduction. An ultrasound probe (3.5 MHz) was placed between intercostal spaces and perpendicularly to the skin. A vibrator located on the probe sent low-frequency (50 Hz) shear waves into the right liver lobe. This specific probe is an emitter-receptor that measures the velocity of the waves propagated within the liver tissue.

The signal recorded during the ultrasound test is represented through an elastogram reflecting the depth of propagation as a function of the acquisition time. The liver stiffness (Young's modulus) is represented by the slope of the straight line. Young's modulus was calculated as an average of 20 validated measurements, corresponding to a success ratio $\geq 60\%$ with an interquartile range $<30\%$. Moreover, the acquisitions were defined as valid when the shape of the signal recorded during the ultrasound test revealed a crimp behavior reflecting the hepatic tissue. The waves were propagated at a depth of 60 mm, and Young's modulus was calculated with the following equation: $E = 3\mu$.

Biopsy being a risky and an unnecessary procedure for alcoholic patients, the Fibroscan exam was used as the reference technique to identify the level of fibrosis (F_S), and the distribution of the patients was composed as follows: $F0_S$ ($N = 18$), $F1_S$ ($N = 20$), $F2_S$ ($N = 27$), $F3_S$ ($N = 12$), and $F4_S$ ($N = 13$).

Magnetic Resonance Elastography

The subjects lay supine on a 1.5 T Signa HDx MRI machine (General Electric, Milwaukee, WI), and the center of a cylindrical acoustic driver (diameter: 16 cm) was placed at the same level as the diaphragm and positioned in contact with the rib cage. The body coil was used, and the acoustic driver had a long hose connected to a large active loudspeaker. This system created time-varying pressure waves propagating shear waves within the abdomen at 60 Hz. MRE images were collected with a motion-sensitized gradient-echo sequence, collected at 2 time offsets (phase offsets) between the start of the motion and the motion encoding gradients, using a single number of gradients. Two offsets were recorded in a row, and during this acquisition, the subjects held their breathing to avoid the motion of the liver caused by the displacement of the diaphragm. The total scan time recorded was 32 seconds corresponding to 2 breath-holding periods of 16 seconds.

The acquisition matrix was 256×64 (which was interpolated to 256×256), the flip angle was 30° , the field of view was between 34 and 48 cm in function of the morphology of the subject, the receiver

bandwidth was 15.63 kHz, and the frequency direction was R/L. According to the MRE parameters, the TR was 100 ms and the TE corresponded to the minimum echo time (26.8 ms) that allowed for motion encoding.

MRE axial images were recorded for each patient in the same liver region where the Fibroscan was performed. Phase images (Fig. 1A,C,E) showed the shear wave displacement within the liver tissue, and the cartography of the shear modulus (μ) (Fig. 1B,D,F) revealed the distribution of the liver stiffness. The mapping of stiffness was automatically generated from the masked wave displacement image (prefiltered with a fourth-order band-pass filter) using the local frequency estimation algorithm (Manduca et al., 2001). Assuming that the liver tissue is locally homogeneous, the regions of interest (ROIs), which were composed of 2 front waves, were placed around fibrotic areas to measure the average stiffness and to analyze the localization of the fibrosis within the liver. Minor fibrosis (F1 and F2) exhibited smaller wavelength (Fig. 1A) than severe fibrosis (Fig. 1E), and therefore the ROI was placed in the superior right lobe (i.e., in the anterior liver area; Fig. 1D) while larger ROI, representing the entire liver, were drawn for severe (F3 and F4) fibrosis. Repeatability of MRE acquisitions was conducted on each subject, on the same day but at different times.

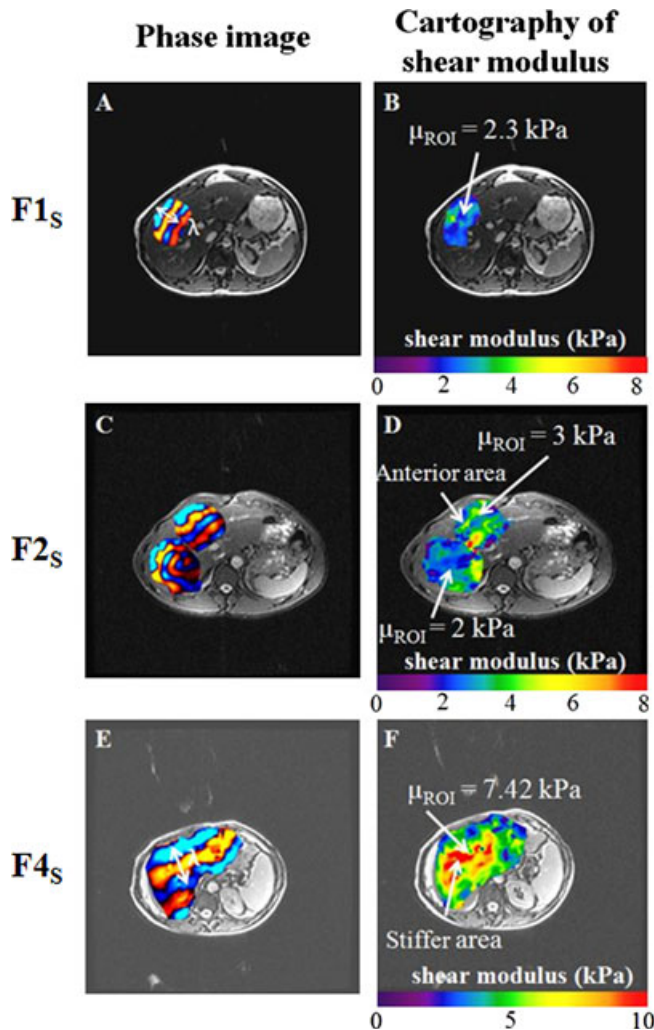


Fig. 1. Phase images (A, C, E) showing the propagation of the shear waves (λ : wavelength) inside the liver of alcoholic patients, and the corresponding cartography of shear modulus (μ) (B, D, F) representing the liver stiffness measured inside selected regions of interest (ROIs).

Laboratory Tests

In addition to the stiffness measurement, a laboratory test was analyzed to assess the fibrosis level. Thus, the Fibrometer A (Bio-LiveScale, Angers, France) calculated the intermediate stages (F0, F0/1, F1/2, F2/3, and F4) of the liver fibrosis for each patient, as a function of the following parameters: prothrombin time, Alpha2 macroglobulin, hyaluronic acid, and the age of the patient (Calès et al., 2005). It should be noted that the Fibrometer A is a test that provides a combination of the intermediate grades.

Statistical Analysis

A Spearman correlation test was used to evaluate the correlation between the level of fibrosis and the imaging (Fibroscan, MRE) techniques as well as the laboratory test (Fibrometer A).

Paired *t*-tests were performed to compare the stiffness measurements between the successive intermediate (from F0 to F4) liver stages measured for each technique. In addition, paired *t*-tests were also used to compare the liver stiffness data, at each intermediate level, obtained between the Fibroscan and MRE techniques.

The diagnostic performance of the MRE technique as well as the Fibrometer A was performed by using the cutoffs of the Fibroscan, validated for alcoholic patients, and with the receiver-operating characteristic (ROC) curves leading to the analysis of the following parameters: sensitivity, specificity, positive predictive value (PPV), and negative predictive value (NPV). Moreover, the area under the ROC curve (AUROC) was analyzed to define the performance of the applied methods. Then, from the ROC curve, the Youden index, equal to the sensitivity + specificity - 1, was maximized to quantify the cutoff values for the MRE and the Fibrometer A.

All the statistical tests were significant for a $p < 0.05$ as calculated using the software Statgraphics 5.0 (Sigma Plus, Maryland, USA).

RESULTS

Comparison of the Liver Stiffness Obtained with Imaging (Fibroscan, MRE) Techniques and the Laboratory (Fibrometer A) Test Using the Fibroscan Alcoholic Cutoffs

The Spearman correlation revealed that the MRE technique is a better method ($r = 0.817$) to identify the different levels of fibrosis for alcoholism disease compared with the Fibrometer A ($r = 0.496$) tests.

Figure 1 shows an increase of the wavelength with the level of fibrosis, leading to stiffer areas located within the cartography of the shear modulus. It can be noticed that alcoholic patients F2_s revealed a stiffer region (about 1 kPa) in the anterior area of the liver (Fig. 1D), indicating the possible starting point of the fibrosis. Figure 2 also showed the evolution of the liver fibrosis characterized with the 3 different tests, which revealed an increase in the stiffness measurement and an increase in the liver score with the level of fibrosis. As expected, the Fibroscan technique revealed a significant liver stiffness difference (Fig. 2A) between all the intermediate stages, while the MRE technique did not succeed to differentiate the stages F1_s from F2_s (Fig. 2B) by using the cutoff values previously established for the Fibroscan. The results obtained with the Fibrometer A (Fig. 2C) showed only significant ($p < 0.05$) score differences between the severe (F3 and F4) fibrosis levels.

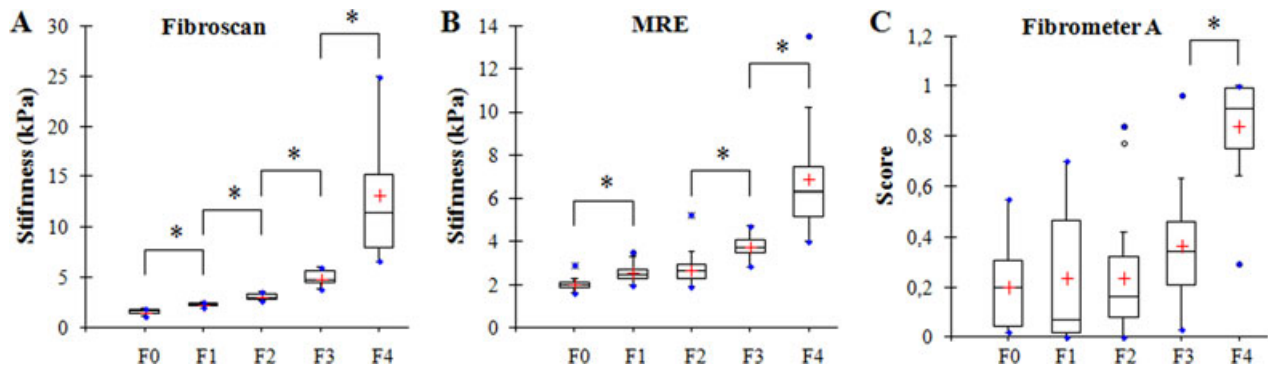


Fig. 2. Evolution of the alcoholic liver fibrosis using imaging techniques (**A:** Fibroscan and **B:** MRE) and laboratory test (**C:** Fibrometer A) ($*p < 0.05$).

Figure 3 compared the mean shear stiffness measured with the imaging (MRE and Fibroscan) techniques. The results were in the same range even though it was determined that there was a slight but significant difference ($p < 0.05$) in stiffness between both techniques, for all fibrosis levels. The present comparison is in agreement with the literature (Bensamoun et al., 2008; Huwart et al., 2008). A strong increase in the shear stiffness was revealed for both imaging techniques in alcoholic patients F4_s due to the composition of this group made up of more severe fibrosis, and other factors such as hepatic inflammation, portal pressure, and so on. In addition, the comparison of the standard deviation between MRE and Fibroscan techniques revealed a higher variation for the Fibroscan.

Comparison of the Diagnostic Performance Between MRE and Fibrometer A Tests

Figure 4 shows the results of the areas calculated under the ROC curve, and it was found that the MRE technique is a method with a high diagnostic performance for the identification of all the intermediate alcoholic liver stages while the Fibrometer A is adapted to identify only severe alcoholic fibrosis (F4).

Table 1 summarizes the different MRE parameters (cutoff, sensitivity, specificity, PPV, NPV) obtained from the ROC analysis dedicated to alcoholism disease. The results of the MRE cutoff for all patients are F1_{MRE}: 2.20 kPa, F2_{MRE}: 2.57 kPa, F3_{MRE}: 3.31 kPa, and F4_{MRE}: 4 kPa. It must be noticed that the GOT level did not influence the MRE cutoff values. The calculated Fibrometer A cutoff values were F1_{Fibrometer}: 0.63 kPa, F2_{Fibrometer}: 0.71 kPa, F3_{Fibrometer}: 0.27 kPa, and F4_{Fibrometer}: 0.64 kPa. It can be noticed that the cutoffs did not vary from the level F1_{Fibrometer} to F4_{Fibrometer}, indicating that the Fibrometer A is not adapted to depict intermediate liver fibrosis.

Then, a new distribution of the fibrosis levels for alcoholic patients was made using the MRE cutoffs (Table 2). The results showed that 66% of patients had a similar liver fibrosis as those defined with the Fibroscan cutoffs attributed to alcoholism. Table 2 indicates that Fibroscan and MRE provide a similar distribution for inexistent fibrosis (F0) and for severe fibrosis (F3). However, these imaging techniques did not provide the same distribution for minor fibrosis (F1 and F2). Indeed, 20 and 27 patients were classified as F1_s and F2_s, with the Fibroscan technique, respectively, while the new MRE classification indicated 17 and 22 patients for the groups F1_{MRE} and F2_{MRE}, respectively.

DISCUSSION

The originality of this study is to take into consideration the etiology of the liver pathology to set up cutoff values to properly differentiate the intermediate levels of fibrosis for alcoholic patients, which can ultimately be used for accurate noninvasive clinical diagnosis.

The comparison of the 3 different tests (Fibroscan, MRE, and Fibrometer A) revealed that the Fibrometer A test can be used to depict severe alcoholic fibrosis while both imaging techniques were able to differentiate the intermediate fibrosis levels. Fibroscan and MRE are complementary imaging techniques characterizing locally and globally the liver tissue, respectively. In a previous study (Bensamoun et al., 2008), similar stiffnesses were found between Fibroscan and MRE methods for healthy subjects demonstrating the capability of the MRE technique to measure healthy liver. The same con-

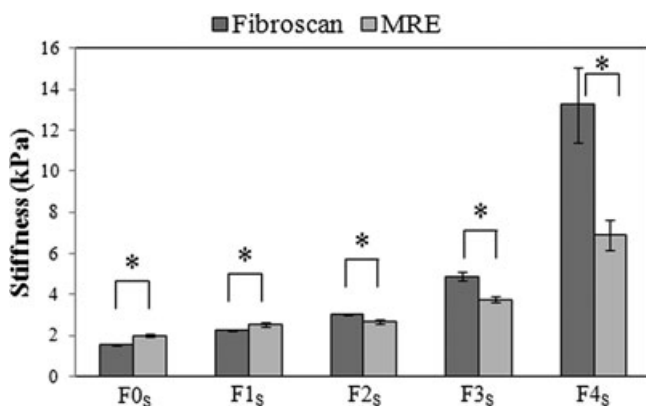


Fig. 3. Comparison of the mean shear stiffness measured with the Fibroscan and MRE techniques ($*p < 0.05$) for all the intermediate liver fibrosis.

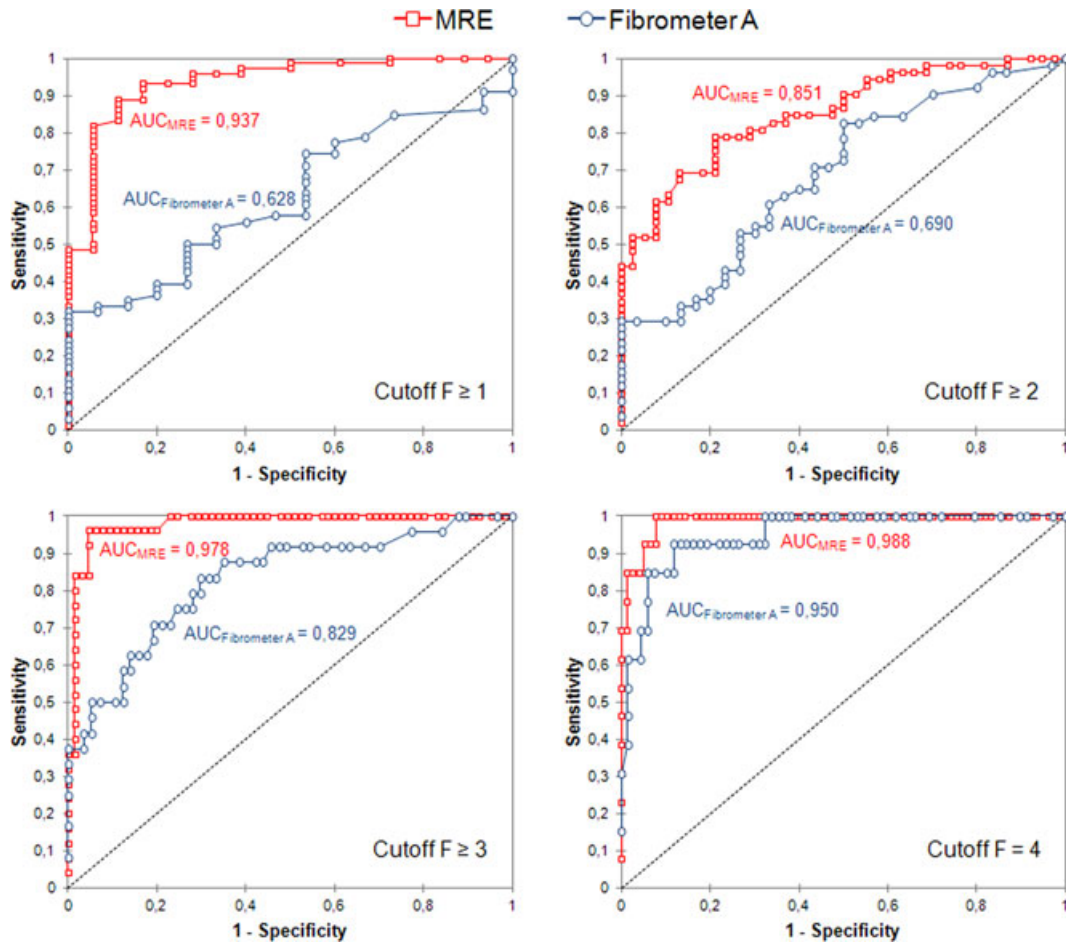


Fig. 4. Comparison of the ROC curves obtained from MRE experiments and Fibrometer A test for moderate and severe liver fibrosis for all patients. Areas under the ROC curves (AUCs) for both tests were measured with 95% confident interval, for the different intermediate liver alcoholic fibrosis, using the Fibroscan technique as the reference.

Table 1. MRE Cutoff Values as Well as the Sensitivity, Specificity, PPV, and NPV Obtained for All Alcoholic Patients (N = 90) and Subsequently for Patients with a GOT <100 U/l (N = 65), and Patients with GOT <50 (N = 48)

		F1 _{MRE}	F2 _{MRE}	F3 _{MRE}	F4 _{MRE}
MRE cutoff (kPa)	All patients	2.20	2.57	3.31	4.00
	GOT <100 U/l	2.20	2.59	3.31	4.00
	GOT <50 U/l	2.20	2.59	3.31	4.00
Sensitivity	All patients	0.889	0.788	0.960	1.000
	GOT <100 U/l	0.894	0.786	1.000	1.000
	GOT <50 U/l	0.969	0.800	1.000	1.000
Specificity	All patients	0.889	0.789	0.954	0.922
	GOT <100 U/l	0.889	0.811	0.981	0.949
	GOT <50 U/l	0.875	0.857	1.000	0.933
PPV	All patients	0.970	0.837	0.889	0.684
	GOT <100 U/l	0.955	0.759	0.923	0.667
	GOT <50 U/l	0.939	0.800	1.000	0.500
NPV	All patients	0.667	0.732	0.984	1.000
	GOT <100 U/l	0.762	0.833	1.000	1.000
	GOT <50 U/l	0.933	0.857	1.000	1.000

GOT, glutamic oxaloacetic transaminase; MRE, magnetic resonance elastography; NPV, negative predictive value; PPV, positive predictive value.

clusion was found in the present study for alcoholism liver disease. Standard deviations for F4 patients showed a greater variation for the Fibroscan technique, revealing its sensitivity to local stiffness measurements. Indeed, F4 patients presenting liver tissue changes such as thicker subcutaneous fat tissue above the ribs, a more important blood flow circulation as well as a high heterogeneous local tissue, the placement of the ultrasound probe, as well as the 20 recorded acquisitions, could be difficult leading to a higher range of liver stiffness obtained with the Fibroscan compared with the MRE technique, which is less influenced by the intrinsic liver modifications. MRE method provides cartography of stiffness allowing for the visualization of fibrotic regions within the entire liver, and this information is of importance for the follow up of liver disease. Moreover, the cartographies of stiffness, corresponding to F2_S patients, and revealing fibrotic areas in the anterior zone could be used as an indicator for the clinician to investigate possible areas of fibrosis (for patient F2_S) by placing the ultrasound probe in this region.

In the literature, studies have characterized the AUROC and it was demonstrated that the Fibroscan technique was

Table 2. New Distribution of the Intermediate Fibrosis Levels for the Alcoholic Patients Using the Present MRE Cutoffs

Initial distribution with Nguyen-Khac's cutoffs (Arena et al., 2008; Nguyen-Khac et al., 2008) (F_S)	Fibrosis stage with MRE				
	$F_{0_{MRE}}$ [0–2.20]	$F_{1_{MRE}}$ [2.20–2.57]	$F_{2_{MRE}}$ [2.57–3.31]	$F_{3_{MRE}}$ [3.31–4.00]	$F_{4_{MRE}}$ [4.00– ∞]
F_{0_S} ($N = 18$)	16	1	1		
F_{1_S} ($N = 20$)	3	10	6	1	
F_{2_S} ($N = 27$)	5	6	14	1	1
F_{3_S} ($N = 12$)			1	6	5
F_{4_S} ($N = 13$)					13
Distribution with MRE cutoffs (F_{MRE})	24	17	22	8	19
Distribution with Huwart's cutoff (Huwart et al., 2008) (F_{Huwart})	36	1	22	16	15

MRE, magnetic resonance elastography.

Numbers in bold correspond to the same liver fibrosis classification measured with the Fibroscan and MRE techniques.

found to be more adapted than the Fibrometer A for alcoholism liver pathology (Arena et al., 2008; Nguyen-Khac et al., 2008), and less adapted than MRE technique from a study performed on different liver etiologies (Huwart et al., 2008). AUROC was mainly built using the biopsy as the gold standard while in the present study the Fibroscan was used as the reference. However, due to the risk of this exam for the patients, and the unnecessary procedure for the present recruited alcoholic patients, the Fibroscan method was chosen as the gold standard. We are conscious that none of the imaging techniques could replace the gold standard of the biopsy, even though biopsy may also provide an error of 25% (Friedman, 2008), and the extracted sample may not be representative of the entire liver volume. The AUROC corresponding to the Fibrometer A and calculated for the intermediate fibrosis levels of the present study were in the same range as the one of Nguyen-Khac's study until stage F3, while a higher performance was found for the most severe stage F4 (0.950 vs. 0.85 for Nguyen-Khac's study). This may be due to the lower number of F4 patients recruited in the present study. Moreover, the comparison of the AUROCs obtained with MRE technique revealed similar data as Huwart and colleagues (2008) for patients suffering from different liver pathologies, suggesting that the AUROC is not sensitive to the liver etiology.

According to this present study, the MRE cutoff values, calculated for all patients, cannot be correlated to those found by Nguyen-Khac's study, for the same type of liver disease, using the standard equation $E_{\text{cutoffs_TE}} =$

$3 \mu_{\text{cutoffs_MRE}}$ (Table 3). The comparison of MRE and TE cutoffs revealed that patients will be more easily diagnosed F1 using the Fibroscan ($F_{1_{\text{Nguyen-Khac}}}$: 1.96 kPa) while using MRE cutoffs ($F_{1_{\text{MRE}}}$: 2.2 kPa) the patients will be diagnose healthy, that is, F0 (Table 3). Conversely, F4 patients will be more easily diagnosed at this level with MRE cutoffs ($F_{4_{\text{MRE}}}$: 4 kPa) than using the Fibroscan ($F_{4_{\text{Nguyen-Khac}}}$: 6.5 kPa) technique. The comparison of the present MRE cutoffs for alcoholic patients with those already established by Huwart and colleagues' study (2008) using MRE tests performed on liver disease from different etiologies revealed a higher stiffness difference between the cutoffs of levels F1 and F2 ($\Delta_{F1/2_{\text{Alcoholism}}} = 0.37$ kPa vs. $\Delta_{F1/2_{\text{Huwart}}} = 0.07$ kPa), indicating a better accurate evaluation of moderate fibrosis using the new setup of MRE cutoffs (Table 3). Indeed, by using Huwart's MRE cutoffs, it is almost impossible to differentiate the fibrosis level F1 from F2. Concerning the stiffness interval between the cutoffs for the levels F2 and F3, the present stiffness difference ($\Delta_{F2/3_{\text{Alcoholism}}} = 0.74$ kPa) is in agreement with Huwart's study. However, the stiffness difference between the cutoffs of levels F3 and F4 remaining stable ($\Delta_{F3/4_{\text{Alcoholism}}} = 0.69$ kPa) for the present alcoholism study, compared with Huwart's study who exhibited a larger interval ($\Delta_{F3/4_{\text{Huwart}}} = 1$ kPa). Thus, with the new set up of MRE cutoffs, it is more difficult to classify patients $F \geq 3$ compared with the MRE cutoffs of Huwart. To characterize the impact of the cutoffs on the liver staging, a new distribution of the present alcoholic patients was made using the MRE cutoff values of Huwart's studies. The result showed

Table 3. Comparison of the Published Cutoff Values from Magnetic Resonance and Ultrasound Elastography Techniques

		Cutoffs referenced in the literature						
		F1		F2		F3		F4
MRE technique	Huwart and colleagues (2008) (F_{Huwart})	2.42	0.07	2.49	0.64	3.13	1.00	4.13
MRE technique	Present cutoffs for alcoholism disease ($F_{\text{Alcoholism}}$)	2.20	0.37	2.57	0.74	3.31	0.69	4.00
Fibroscan	Nguyen-Khac and colleagues (2008) ($F_{\text{Nguyen-khac}}$)	1.96	0.64	2.60	1.10	3.66	2.80	6.50

MRE, magnetic resonance elastography.

that only 1 patient was diagnosed as F1 using Huwart's cutoffs, while a total of 17 patients were diagnosed F1 with the present MRE cutoffs (Table 2). Even if these changes of distribution concern moderate fibrosis, the present study demonstrates an effect of the cutoff values on the liver fibrosis classification. In addition, it must be noticed that the variation of the cutoff values obtained between the MRE techniques may be due to the different protocols, which vary in frequency, inversion algorithm (local frequency estimation, phase gradient, and direct inversion), ROI placement in the right or left liver lobes, and so on (Leclerc et al., in press). For instance, a recent study has demonstrated a correlation between the applied range of frequency and the material properties of the clinical liver driver (Leclerc et al., 2012). All these factors may induce a mis-classification of the patients.

The present MRE protocol has been standardized (frequency, liver driver, inversion algorithm, etc.) to be currently used in Europe and the United States as a clinical exam (Nguyen and Talwalkar, 2011). Thus, the present MRE cutoffs could assist clinicians with regard to the diagnosis of liver fibrosis resulting from alcoholism disease. Furthermore, it is necessary to establish cutoff values for the various stages of liver disease to accurately diagnose these patients.

ACKNOWLEDGMENT

Grant support is acknowledged from the Picardie Région.

REFERENCES

- Arena U, Vizzutti F, Corti G, Ambu S, Stasi C, Bresci S, Moscarella S, Boddi V, Petrarca A, Laffi G, Marra F, Pinzani M (2008) Acute viral hepatitis increases liver stiffness values measured by transient elastography. *Hepatology* 47:380–384.
- Bensamoun SF, Wang L, Robert L, Charleux F, Latrive J-P, Ho Ba Tho M-C (2008) Measurement of liver stiffness with two imaging techniques: magnetic resonance elastography and ultrasound elastometry. *J Magn Reson Imaging* 28:1287–1292.
- Calès P, Oberti F, Michalak S, Hubert Fouchard I, Rousselet M, Konaté A, Gallois Y, Ternisien C, Chevaillier A, Lunel F (2005) A novel panel of blood markers to assess the degree of liver fibrosis. *Hepatology* 42:1373–1381.
- Friedman SL (2008) Mechanisms of hepatic fibrogenesis. *Gastroenterology* 134:1655–1669.
- Gelsi E, Dainese R, Truchi R, Marinè Barjoan E, Anty R, Autuori M, Burroni S, Vanbiervliet G, Evesque L, Cherikh F, Tran A (2011) Effect of detoxification on liver stiffness assessed by Fibroscan® in alcoholic patients. *Alcohol Clin Exp Res* 35:566–570.
- Huwart L, Sempoux C, Salameh N, Jamart J, Annet L, Sinkus R, Peeters F, Ter Beek LC, Horsmans Y, Van Beers BE (2007) Liver fibrosis: noninvasive assessment with MR elastography versus aspartate aminotransferase-to-platelet ratio index1. *Radiology* 245:458–466.
- Huwart L, Sempoux C, Vicaut E, Salameh N, Annet L, Danse E, Peeters F, ter Beek LC, Rahier J, Sinkus R, Horsmans Y, Van Beers BE (2008) Magnetic resonance elastography for the noninvasive staging of liver fibrosis. *Gastroenterology* 135:32–40.
- Janssens F, de Suray N, Piessevaux H, Horsmans Y, de Timary P, Stärkel P (2010) Can transient elastography replace liver histology for determination of advanced fibrosis in alcoholic patients: a real-life study. *J Clin Gastroenterol* 44:575–582.
- Kircheis G, Sagir A, Vogt C, vom Dahl S, Kubitz R, Häussinger D (2012) Evaluation of acoustic radiation force impulse imaging for determination of liver stiffness using transient elastography as a reference. *World J Gastroenterol* 18:1077–1084.
- Leclerc GE, Charleux F, Robert L, Ho Ba Tho MC, Rhein C, Latrive JP, Bensamoun SF (in press) Analysis of the liver viscosity behavior as a function of the Multifrequency Magnetic Resonance Elastography (MMRE) post-processing. *J Magn Reson Imaging*.
- Leclerc GE, Debernard L, Foucart F, Robert L, Pelletier KM, Charleux F, Ehman R, Ho Ba Tho M-C, Bensamoun SF (2012) Characterization of a hyper-viscoelastic phantom mimicking biological soft tissue using an abdominal pneumatic driver with magnetic resonance elastography (MRE). *J Biomech* 45:952–957.
- Manduca A, Oliphant TE, Dresner MA, Mahowald JL, Kruse SA, Amromin E, Felmlee JP, Greenleaf JF, Ehman RL (2001) Magnetic resonance elastography: non-invasive mapping of tissue elasticity. *Med Image Anal* 5:237–254.
- Mathurin P (2012) EASL clinical practice guidelines: management of alcoholic liver disease. *J Hepatol* 57: 399–420
- Millonig G, Reimann FM, Friedrich S, Fonouni H, Mehrabi A, Büchler MW, Seitz HK, Mueller S (2008) Extrahepatic cholestasis increases liver stiffness (FibroScan) irrespective of fibrosis. *Hepatology* 48:1718–1723.
- Morra R, Lebray P, Ingiliz P, Ngo Y, Munteanu M, Ratziu V, Poynard T (2008) FibroTest has better diagnostic and prognostic values than the aspartate aminotransferase to platelet ratio index in patients with chronic hepatitis C. *Hepatology* 47:353–354.
- Mueller S, Millonig G, Sarovska L, Friedrich S, Reimann FM, Pritsch M, Eisele S, Stichel F, Longerich T, Schirmacher P, Seitz HK (2010) Increased liver stiffness in alcoholic liver disease: differentiating fibrosis from steatohepatitis. *World J Gastroenterol* 16:966–972.
- Mueller S, Sandrin L (2010) Liver stiffness: a novel parameter for the diagnosis of liver disease. *Hepat Med* 2:49–67.
- Nahon P, Kettaneh A, Tengher-Barna I, Zioli M, de Lédinghen V, Douvin C, Marcellin P, Ganne-Carrié N, Trinchet J-C, Beaugrand M (2008) Assessment of liver fibrosis using transient elastography in patients with alcoholic liver disease. *J Hepatol* 49:1062–1068.
- Naveau S, Gaudé G, Asnacios A, Agostini H, Abella A, Barri Ova N, Dauvois B, Prévot S, Ngo Y, Munteanu M, Balian A, Njiké Nakseu M, Perlemuter G, Poynard T (2009) Diagnostic and prognostic values of noninvasive biomarkers of fibrosis in patients with alcoholic liver disease. *Hepatology* 49:97–105.
- Nguyen D, Talwalkar JA (2011) Noninvasive assessment of liver fibrosis. *Hepatology* 53:2107–2110.
- Nguyen-Khac E, Chatelain D, Tramier B, Decrombecque C, Robert B, Joly J, Brevet M, Grignon P, Lion S, Le Page L, Dupas J (2008) Assessment of asymptomatic liver fibrosis in alcoholic patients using fibroscan: prospective comparison with seven non-invasive laboratory tests. *Aliment Pharmacol Ther* 28:1188–1198.
- Paille F (2011) Misuse of alcohol and new drug treatments. *Rev Prat* 6: 1386–1391.
- Rockey DC, Bissell DM (2006) Noninvasive measures of liver fibrosis. *Hepatology* 43:S113–S120.
- Sagir A, Erhardt A, Schmitt M, Häussinger D (2008) Transient elastography is unreliable for detection of cirrhosis in patients with acute liver damage. *Hepatology* 47:592–595.
- Shire NJ, Yin M, Chen J, Railkar RA, Fox Bosetti S, Johnson SM, Beals CR, Dardzinski BJ, Sanderson SO, Talwalkar JA, Ehman RL (2011) Test–retest repeatability of MR elastography for noninvasive liver fibrosis assessment in hepatitis C. *J Magn Reson Imaging* 34:947–955.
- Siegel M (2011) Magnetic resonance elastography—new wave of hepatic imaging. *Pediatr Radiol* 41:86–87.
- Trabut JB, Thépot V, Nalpas B, Lavielle B, Coscinea S, Corouge M, Vallet-Pichard A, Fontaine H, Mallet V, Sogni P, Pol S (2012) Rapid decline of liver stiffness following alcohol withdrawal in heavy drinkers. *Alcohol Clin Exp Res* 36:1407–1411.