



HAL
open science

Use of digital image correlation and ultrasound: analysis of thigh muscle displacement fields

Jean-Sebastien Affagard, Pierre Feissel, Sabine F Bensamoun

► To cite this version:

Jean-Sebastien Affagard, Pierre Feissel, Sabine F Bensamoun. Use of digital image correlation and ultrasound: analysis of thigh muscle displacement fields. 2015 37th Annual International Conference of the IEEE Engineering in Medicine and Biology Society (EMBC), Aug 2015, Milan, France. pp.3827-3830, 10.1109/EMBC.2015.7319228 . hal-03893831

HAL Id: hal-03893831

<https://utc.hal.science/hal-03893831v1>

Submitted on 11 Dec 2022

HAL is a multi-disciplinary open access archive for the deposit and dissemination of scientific research documents, whether they are published or not. The documents may come from teaching and research institutions in France or abroad, or from public or private research centers.

L'archive ouverte pluridisciplinaire **HAL**, est destinée au dépôt et à la diffusion de documents scientifiques de niveau recherche, publiés ou non, émanant des établissements d'enseignement et de recherche français ou étrangers, des laboratoires publics ou privés.

Use of digital image correlation and ultrasound: analysis of thigh muscle displacement fields

Jean-Sébastien Affagard, Pierre Feissel, Sabine F. Bensamoun

Abstract - The understanding of the mechanical behavior of the muscle tissue is an important field of investigation with different applications in medicine, car crash and sport. Currently, few *in vivo* imaging techniques are able to characterize the mechanical properties of muscle. Thus, the development of an *in vivo* identification method is a current thematic where the displacement field measurements could be used for further interpretations. This study aims at presenting the displacement fields measured in the anterior, posterior, lateral and medial parts of the thigh muscles using ultrasound and Digital Image Correlation (DIC) techniques. The results of the displacement field measurements confirmed and are correlated with the ultrasound observations.

Index Terms - Thigh muscle, digital image correlation, ultrasound images, displacement fields.

I. INTRODUCTION

The clinician often use palpation techniques to determine the level of pathologies. Nevertheless, an objective indicator is needed to have a fine assessment. In this context, the muscle mechanical behavior of soft tissues could be used.

Currently, to complete the structural analysis obtained with US (Ultrasound) or MRI (Magnetic Resonance Imaging), elastography techniques enable the assessment of the muscle viscoelastic properties [1-3]. Moreover, the soft tissues are complex and are well-known to have a nonlinear and quasi incompressible behavior. Consequently, the analysis of these behaviors could have a diagnostic interest for clinicians. In addition, a better understanding of the behavior of soft tissues has a beneficial effect in the biomechanical modeling of human body. Thus, to further analyze these characteristics, experimental tests and numerical tools were used to measure the muscle displacement field.

A way to identify the hyperelastic behavior of muscle tissues was to perform a FEMU (Finite element Model Updating) on displacement contours of the muscle, bone and adipose tissues between MRI acquisitions and simulation. This identification allowed to identify the hyperelastic behavior of the arm and calf muscles [4, 5]. In these cases, the measurement was limited on the contours of the muscles and a full-field displacement may have a beneficial effect on the identified hyperelastic properties of skin and muscle. The identification error was presented from a numerical example which mimics a full-field displacement of soft tissue [6-7].

A way to measure the displacement and strain fields was developed on the nineteen, [8-10] and consisted in correlating the B-mode signal [11, 12]. Currently, tumors from breast tissue were discerned using the spatial distribution of the hyperelastic material properties [4, 13]. From this cross-correlation technique, Han et al. [14] acquired ultrasound images on phantom, under several static loadings, to measure the 2D and 3D displacement and strain fields. Another way to measure the displacement field is to apply DIC (Digital Image Correlation) [16, 17, 18], often used in the mechanical field.

In a previous study, we have applied this technique on ultrasound acquisitions to measure the displacement field on a phantom, composed of inclusions, and then on the anterior part of the thigh [19]. The present study is a continuity of our previous work and aims at presenting the other displacement fields measured in the lateral, medial and posterior parts of the thigh using ultrasound and DIC techniques.

II. MATERIALS AND METHODS

A. Experimental protocol

The thigh muscle was placed in a home-made compression device [18] composed of three plates (Fig.1). *In vivo* experiments were performed on the thigh muscles of a 33 year old male without venous pathologies. The lower plate was only used as a support for the leg. The two upper ones can be moved down (along the axial axis, *i.e.* the beam ultrasound axis) to compress the muscle and has a specific design to fit the ultrasound probe (9MHz). Moreover, sensors (Tekscan) were placed between the two upper plates in order to quantify the distribution of pressure.

The ultrasound probe was placed in the lower third part of the thigh due to the low amount of adipose tissue allowing a better strain of the muscle tissue. The US acquisitions were performed in anterior (Fig.2A), posterior areas (Fig.2B),

*Research supported by Sorbonne University, Université de Technologie de Compiègne. This project is co-financed by the European Union engaged in Picardy with the European Regional Development Fund and CNRS (grant Collegium UTC CNRS INSIS).

J-S. Affagard is with the UMR CNRS 7338 - Biomechanics and Bioengineering and UMR CNRS 7337 - Laboratoire Roberval, Sorbonne University, University of Technology of Compiègne, BP 20529, 60205 Compiègne cedex, France.

P. Feissel is with the UMR CNRS 7337 - Laboratoire Roberval, Sorbonne University, University of Technology of Compiègne, BP 20529, 60205 Compiègne cedex, France.

S. F. Bensamoun is with the UMR CNRS 7338 - Biomechanics and Bioengineering, Sorbonne University, University of Technology of Compiègne, BP 20529, 60205 Compiègne cedex, France (Corresponding author: 33 3 44 23 43 90/ sabine.bensamoun@utc.fr).

lateral (Fig.2C) and medial (Fig.2D) to have displacement data within each thigh muscle. The anterior area was composed of the vastus medialis (VM) and vastus intermedius (VI). The posterior area was composed of the biceps femoris and the semitendinosus, the lateral area of the vastus lateralis (VL) and the vastus intermedius (VI). Finally, the medial area was composed of the gracilis (Gr) and sartorius (Sr).

To minimize the measurement noise, the US images were acquired with parameters (frequency, gain, dynamic, etc...) set up as optimal [6].

B. Displacement field measurement

The displacement field was measured between uncompressed and compressed muscle images using the DIC method, based on the grey level comparison [15, 16]. To facilitate the convergence of the image correlation, five consecutively images with a loading step of 15N were acquired to obtain the displacement field between the first and the last level of stress (0 to 60N).

Cartographies representing the lateral (X) and axial (Y) displacement fields (Figure 3) were obtained from experimental protocols.

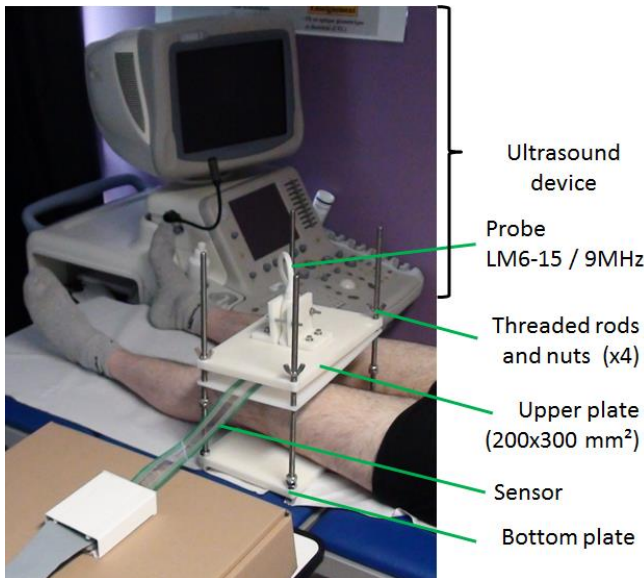


Figure 1. Home-made compression device

III. RESULTS

A. Analysis of the displacement within the anterior area

The anterior part was previously analyzed [18] and is briefly summarized hereafter. The ultrasound acquisition revealed a sliding between both vasti muscles (VM and VI) around the aponeurosis (Fig.3A, 3B). The result of the displacement field (Fig.3C) measured along the axial (X) axis, showed highest displacements (about 10mm, red color) close to the fat tissue while any displacement was found around the bone tissue. Fig.3D illustrated the cartography of the displacement field measured along the lateral (Y) axis. A high

displacement gradient (from -5mm to 2mm), indicated by arrows, was observed around the aponeurosis located between the vastus intermedius (VI) and the vastus medialis (VM) muscles. This last result confirmed the qualitative sliding obtained during the compressive test.

B. Analysis of the displacement within the posterior area

The red region of interest used for the DIC was reduced close to the bone tissue due to a lack of texture. This bad speckle may be due to the muscle structure or insufficient signal information. The ultrasound acquisition revealed a higher strain on the right part of the BF muscle (white arrows) (Fig.3E, 3F). This result is confirmed through the axial (X) displacement cartography showing a higher gradient also in the right BF muscle part (Fig. 3G).

Moreover, a decrease of the angle between both aponeurosis (Fig.3E, 3F) occurred and this result was in agreement with the lateral displacement field cartography (Fig.3H) where a high gradient was present.

C. Analysis of the displacement within the medial area

The ultrasound acquisition revealed a high strain in the middle of the of sartorius, and a lateral displacement of this muscle (Fig.3I, 3J). These qualitative observations were confirmed with the displacement cartographies.

Indeed, the sartorius showed a high gradient on the belly region while a low gradient was found on both extremities (Fig.3K). The result of the lateral displacement field (Fig.3L) revealed a displacement of -5 mm on the left side and 5 mm on the right side, attesting the ultrasound observation.

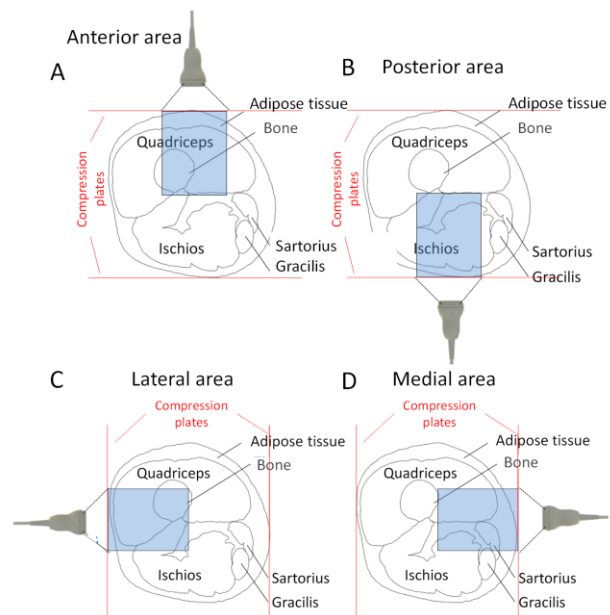


Figure 2. Experimental tests realized in (A) the anterior, (B) posterior, (C) lateral and (D) medial areas.

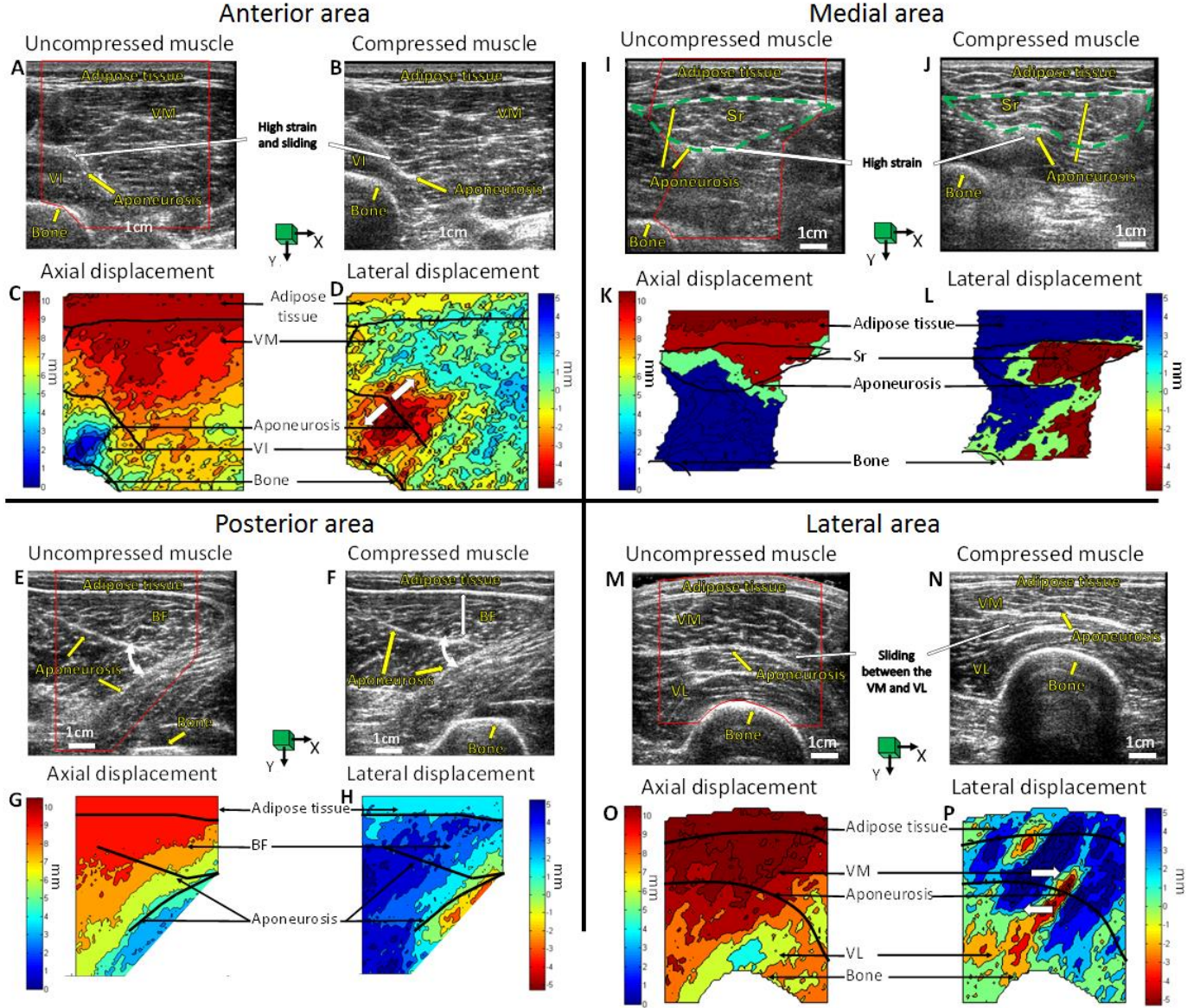


Figure 3. Ultrasound acquisitions on the anterior, posterior, medial and lateral areas of the thigh (A, E, I, M) in the unloaded condition and under a loading (B, F, J, N) of 1 kPa. Horizontal (C, G, K, O) and vertical displacement fields (D, H, L, P). (VM: vastus medialis, VI: vastus intermedius, Sr: sartorius, BF: biceps femoris, VL: vastus lateralis)

D. Analysis of the displacement within the lateral area

During the real-time ultrasound acquisition, a sliding of the vastus medialis (VM) and vastus lateralis (VL) was observed close to the aponeurosis. However, this phenomenon is difficult to identify through only the two present images (Fig.3M, 3N). This sliding is well identified through a displacement discontinuity (white arrows) present around the aponeurosis tissue.

In addition, the higher displacement gradient was located in the middle of the axial displacement cartography (Fig.3O) due to the presence of the bone.

IV. DISCUSSION

This work is the continuity of Affagard's study [18] who has validated the displacement fields with the strain field cartographies calculated using diffuse approximation [19]. This method was firstly validated on a phantom and subsequently applied in vivo on the anterior part of the thigh muscle. The originality of this study was to investigate the other thigh regions to further characterize the muscle behaviors through an inverse approach.

The comparison of the displacement fields between the several areas (Fig.3C, 3G, 3K, 3O) showed similar maximal

axial displacement levels (close to 10mm) with a same applied loading. Moreover, within the adipose tissue, a low strain was observed during the ultrasound acquisition, confirmed through the displacement cartographies where a low gradient was obtained.

For the four thigh regions, the highest lateral gradient was mainly located close to the aponeurosis tissue (Fig.3D, 3H, 3L, 3P). This result is probably related to the muscle structure, which may induce displacement discontinuities, leading to a higher noise measurement in the lateral axis. According to the important level of sliding and strain between muscles, a way to improve the displacement cartographies and then the identification would be to develop an integrated-DIC method to remove the discontinuity problems.

To our knowledge this study is the first to use the DIC method on muscle tissue in order to obtain the displacement field. The limitation of the present study is the measurements obtained from one subject and should be realized on other participants.

Indeed, the quality of images and the mechanical properties of the muscles will differ between individuals, due to the gender, age and health of muscle. Thus, the measured displacement field might be a starting point for the characterization of the in vivo elastic properties and may be extended to the measurement of different soft tissues.

REFERENCES

- [1] L. Debernard, G. E. Leclerc, L. Robert, F. Charleux, and S. F. Bensamoun, "In vivo characterization of the muscle viscoelasticity in passive and active conditions using multifrequency MR Elastography," *Journal of Musculoskeletal Research*, vol. 16, no. 2, pp. 1350008-18, 2013
- [2] J.-L. Gennisson, T. Deffieux, E. Macé, G. Montaldo, M. Fink, and M. Tanter, "Viscoelastic and anisotropic mechanical properties of in vivo muscle tissue assessed by supersonic shear imaging," *Ultrasound in medicine & biology*, vol. 36, no. 5, pp. 789-801, 2010.
- [3] G. E. Leclerc, F. Charleux, L. Robert, M.-C. Ho Ba Tho, C. Rhein, J.-P. Latrive, and S. F. Bensamoun, "Analysis of liver viscosity behavior as a function of multifrequency magnetic resonance elastography (MMRE) postprocessing," *Journal of Magnetic Resonance Imaging*, Vol. 38, no. 2, pp. 422-428, 2013.
- [4] S. Avril, L. Bouten, L. Dubuis, S. Drapier, and J. F. Pouget, "Mixed experimental and numerical approach for characterizing the biomechanical response of the human leg under elastic compression," *Journal of biomechanical engineering*, vol. 132, no. 3, pp. 31006-31014, 2010.
- [5] H. V. Tran, F. Charleux, M. Rachik, A. Ehrlacher, and M.-C. Ho Ba Tho, "In vivo characterization of the mechanical properties of human skin derived from MRI and indentation techniques," *Computer methods in biomechanics and biomedical engineering*, vol. 10, no. 6, pp. 401-407, 2007.
- [6] J.-S. Affagard, S. F. Bensamoun, and P. Feissel, "Development of an inverse approach for the characterization of in vivo mechanical properties of the lower limb muscles," *ASME. J Biomech Eng*, vol. 136(11):111012-111012-8, 2014.
- [7] N.H.Gokhale, P.E. Barbone, A.A. Oberai. "Solution of the nonlinear elasticity imaging inverse problem: the compressible case," *Inverse Problems*, 24(4), 2008.
- [8] J. Ophir, I. Cespedes, H. Ponnekanti, Y. Yazdi, and X. Li, "Elastography: a quantitative method for imaging the elasticity of biological tissues," *Ultrasonic imaging*, vol. 13, no. 2, pp. 111-134, 1991.
- [9] H. Ponnekanti, J. Ophir, and I. Cespedes, "Axial stress distributions between coaxial compressors in elastography: an analytical model," *Ultrasound in medicine & biology*, vol. 18, no. 8, pp. 667-673, 1992.
- [10] H. Ponnekanti, J. Ophir, and I. Cespedes, "Ultrasonic imaging of the stress distribution in elastic media due to an external compressor," *Ultrasound in medicine & biology*, vol. 20, no. 1, pp. 27-33, 1994.
- [11] Y. Zhu, and T. J. Hall, "A modified block matching method for real-time freehand strain imaging," *Ultrasonic Imaging*, vol. 24, no. 3, pp. 161-176, 2002.
- [12] T. J. Hall, P. Barbone, A. A. Oberai, J. Jiang, J. F. Dord, S. Goenez, and T. G. Fisher, "Recent results in nonlinear strain and modulus imaging," *Current medical imaging reviews*, vol. 7, no. 4, pp. 313-327, 2011.
- [13] E. Tönük, and M. B. Silver-Thorn, "Nonlinear viscoelastic material property estimation of lower extremity residual limb tissues," *Journal of biomechanical engineering*, vol. 126, no. (2), pp. 289-300, 2004.
- [14] Y. Han, D. W. Kim, and H. J. Kwon, "Application of digital image cross-correlation and smoothing function to the diagnosis of breast cancer," *Journal of the mechanical behavior of biomedical materials*, vol. 14, pp. 7-18, 2012.
- [15] F. Hild, and S. Roux, "Digital image correlation: from displacement measurement to identification of elastic properties - a review," *Strain*, vol. 42, no. 2, pp. 69-80, 2006.
- [16] F. Hild, and S. Roux, "Correli Q4: A software for-finite-element-displacement field measurements by digital image correlation," *Internal report (269)*, 2008.
- [17] A. Nahas, M. Bauer, S. Roux, A.C. Boccara, "3D static elastography at the micrometer scale using full field OCT," *Biomedical optics express*, vol. 4, no. 10, pp. 2138-2149, 2013.
- [18] J.-S. Affagard, P. Feissel, S.F. Bensamoun, "Measurement of the quadriceps muscle displacement and strain fields with ultrasound and Digital Image Correlation (DIC) techniques," *IRBM*, <http://dx.doi.org/10.1016/j.irbm.2015.02.002>, 2015.
- [19] B. Nayroles, G. Touzot, and P. Villon, "La méthode des éléments diffus," *Comptes rendus de l'Académie des sciences. Série 2, Mécanique, Physique, Chimie, Sciences de l'univers, Sciences de la Terre*, vol. 313, no. 2, pp. 133-138, 1991.